



Ortopedia – fullorðnir

- Sjúkdómafræði -

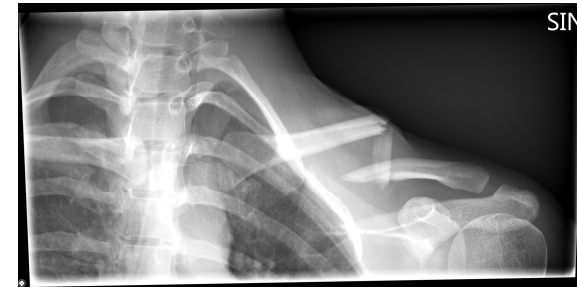
Áverkar (heit ortopedia)

Halldór Jónsson jr

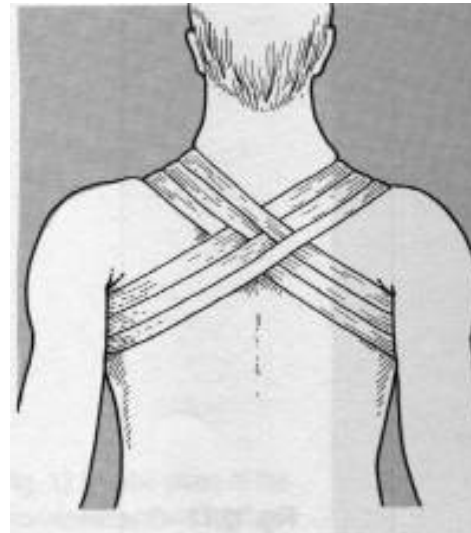
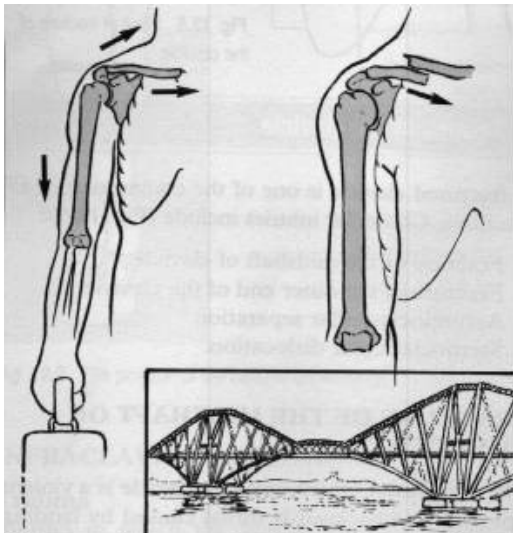
Bæklunarskurðeild LSH og Læknadeild HÍ

Öxl - viðbeinsbrot

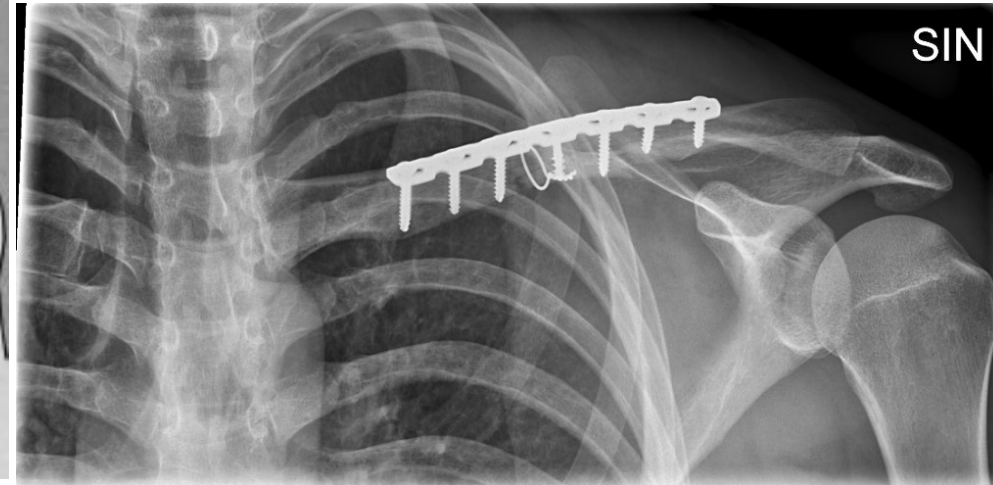- Öxlin dettur niður og inn (Varúð: TOS)
- Ath húð
- Ath lausan flaska og/eða styttingu



Dæmi: 8-tölu bindi

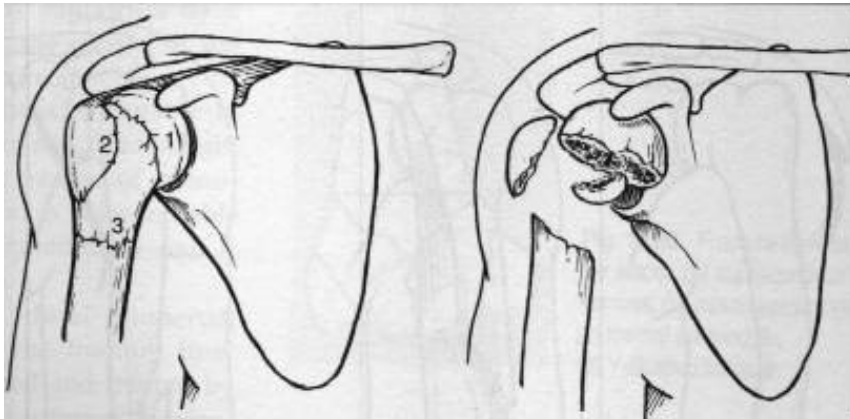


Dæmi: plata og skrúfur og vír

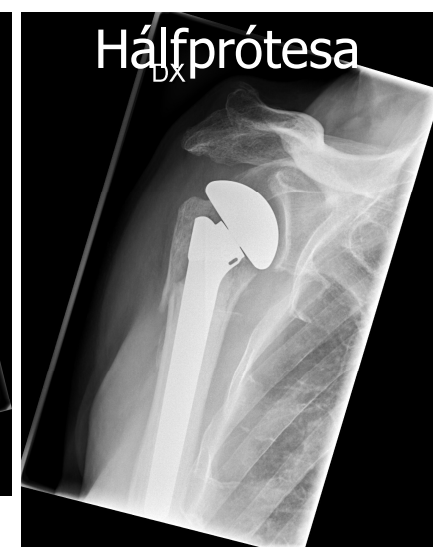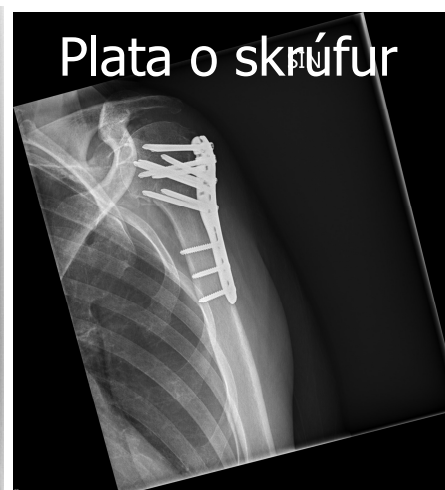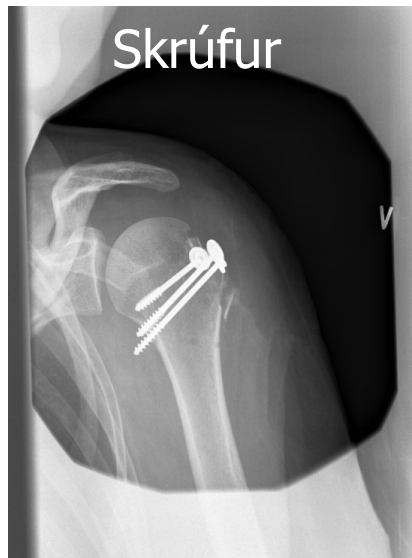
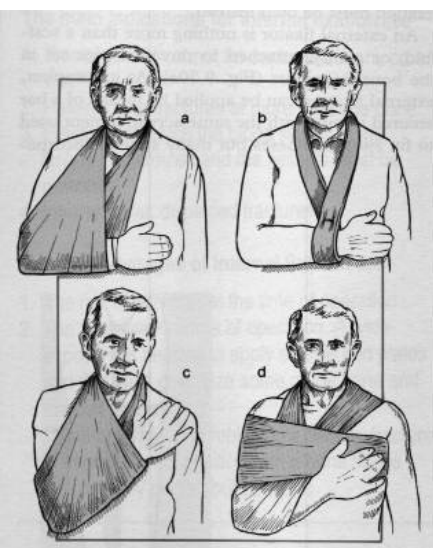


Öxl – efri upphandleggsbrot

- 1. Coll anatomicum, 2. tuberc majus og 3. coll chir

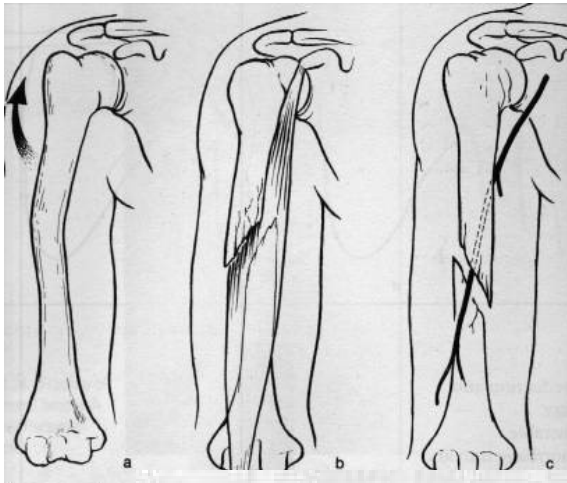


collar 'n cuff (b)

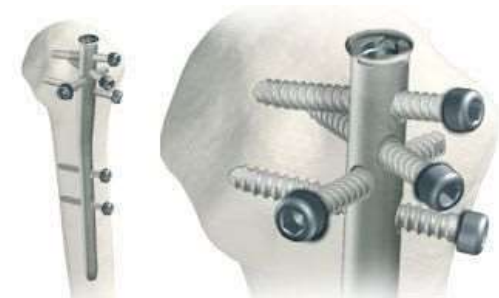
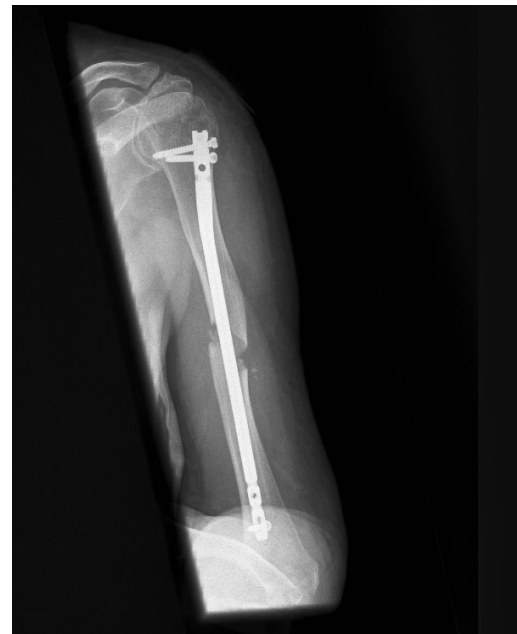
Upphandleggsbrot - skaftið

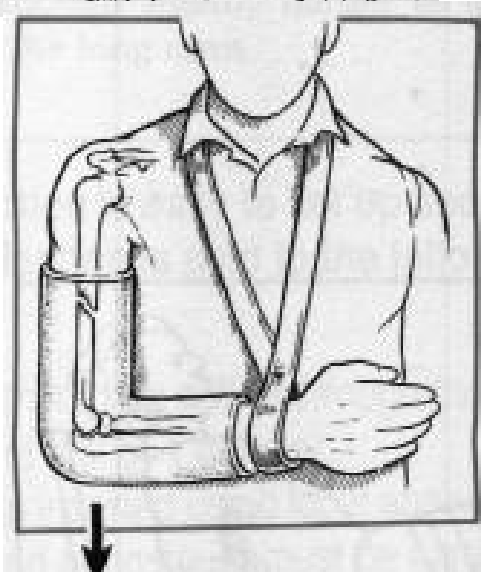- Diafysan



Varúð: N. Radialis
og fallhendi



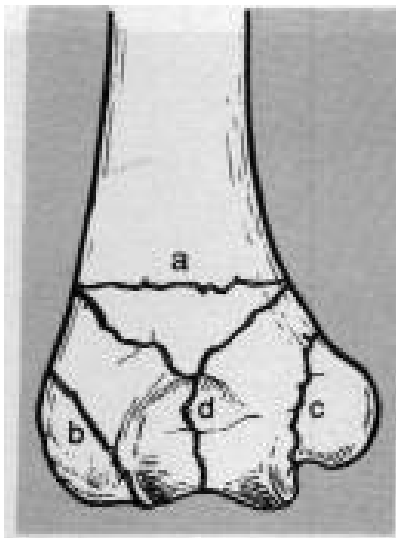
Mergnagli



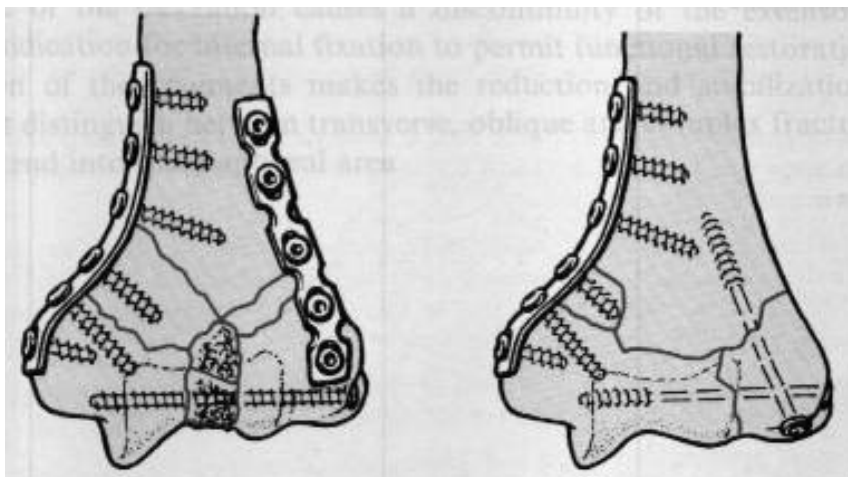
Hanging cast

Olnbogi – fjær upphandleggsbrot

- Varúð: N. Ulnaris; mikill stirðleiki



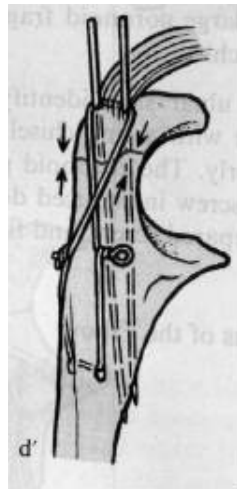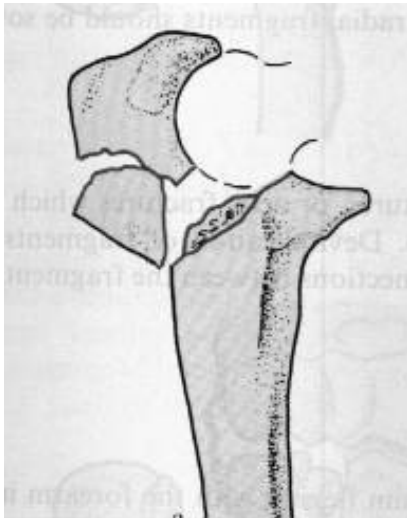
a) supracondylar, (d) transcondylar,
(b) lat epicondyl, (c) med epicondyl



Plötur og skrúfur

Olnbogi – nær framhandleggsbrot

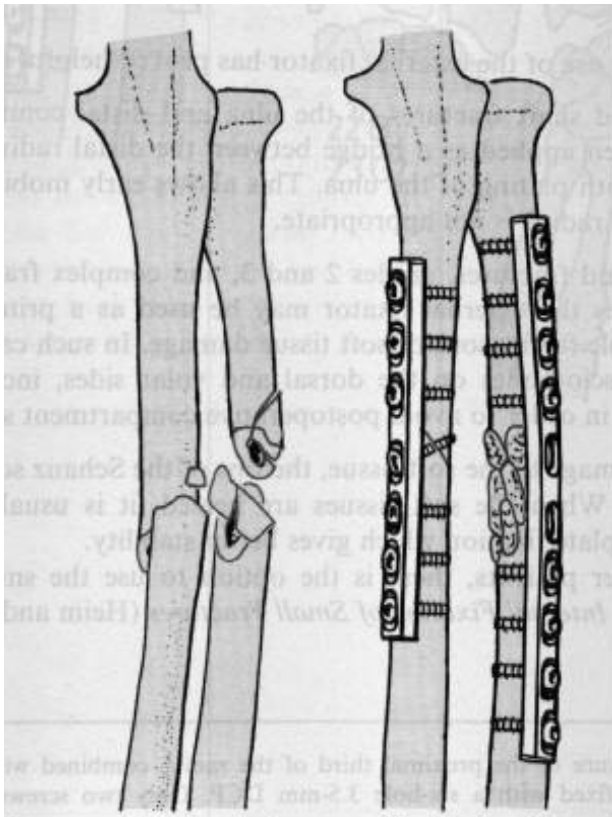
- Olecranon



Stálpinni og vír
(zuggurtung)

Framhandleggsbrot – skaftið

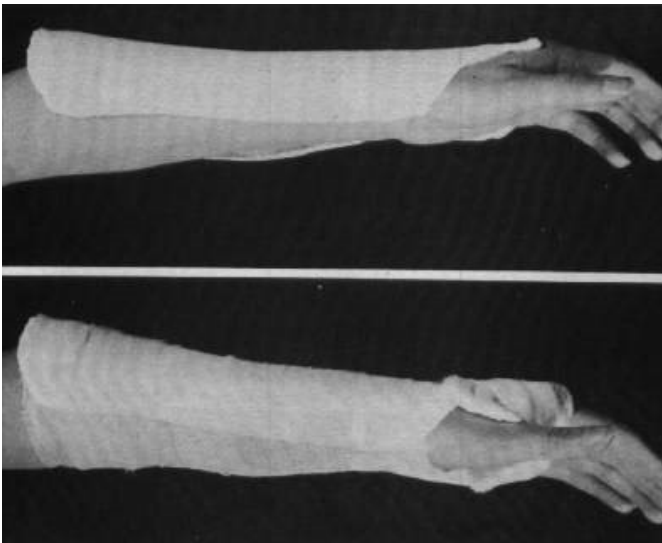
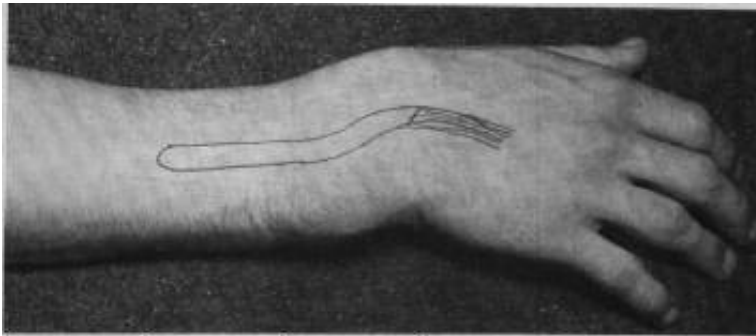
- Báðar pípur; varúð: compartment!



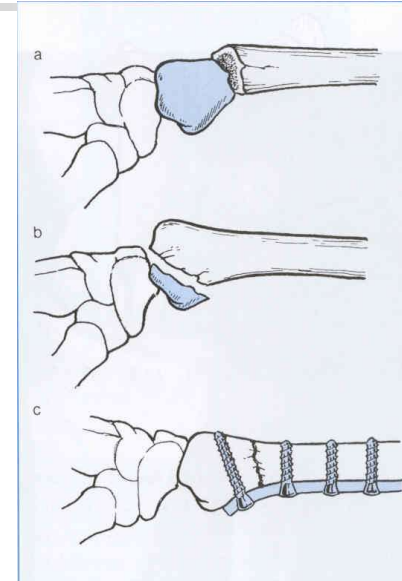
Skrúfur og plötur

Framhandlegggsbrot – úlnliður

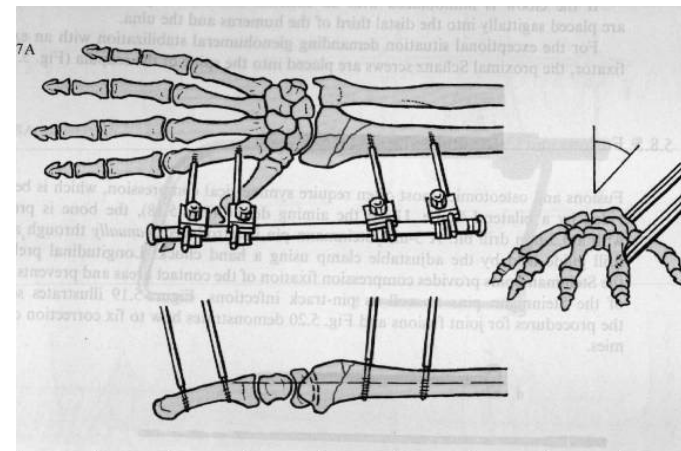
- Colles; varúð: carpal tunnel



Dorsal gifsspelka



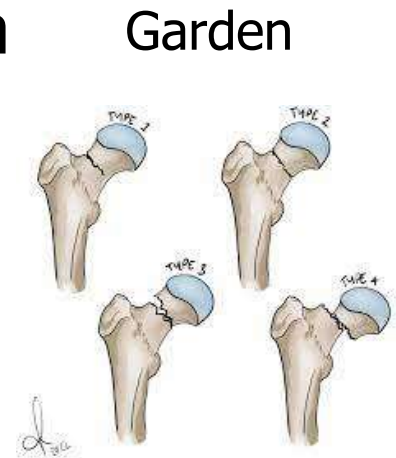
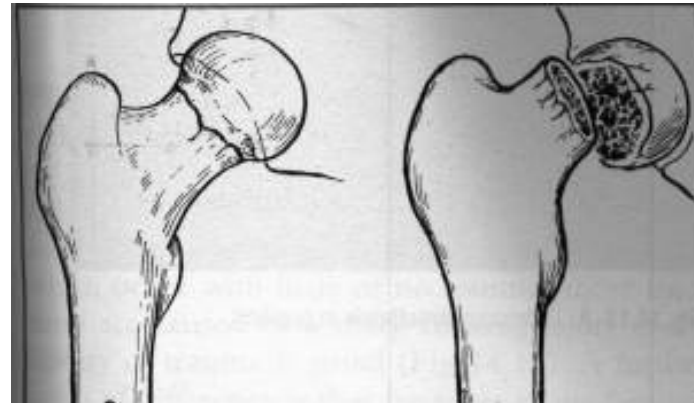
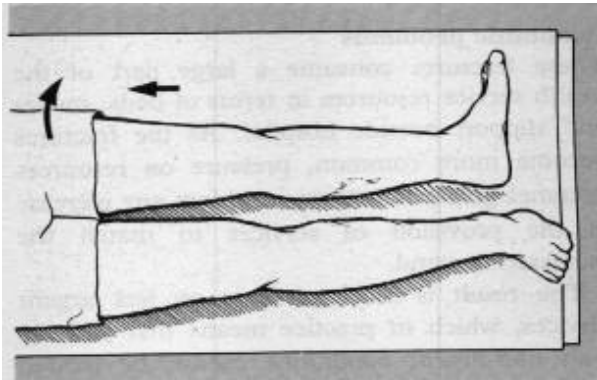
Volar plata



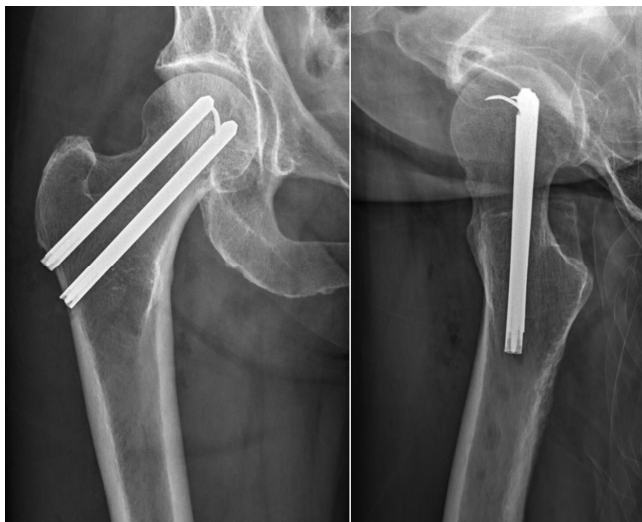Ex fix - Hoffmann

Lærleggssbrot – mjaðmaliður

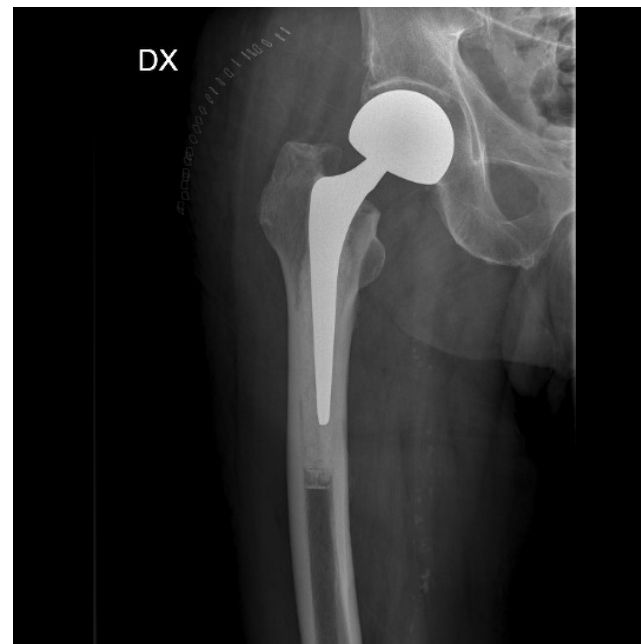- Collum; styttur og útsnúinn – ekki lærbólga



Collum
skrúfur/
naglar
LIH



Lars Ingvar **Hansson**

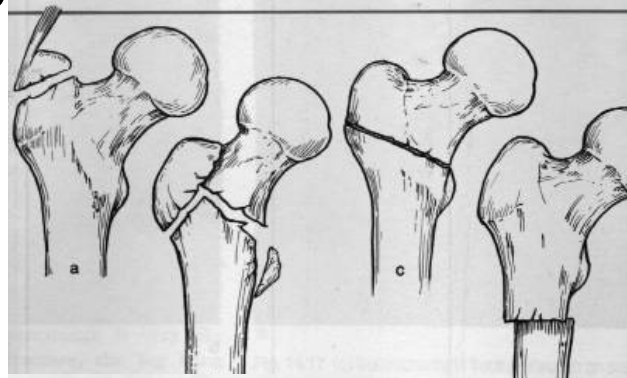
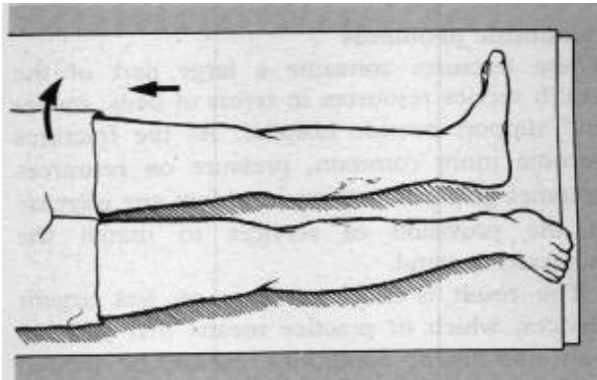


Bi-polar

HJjr

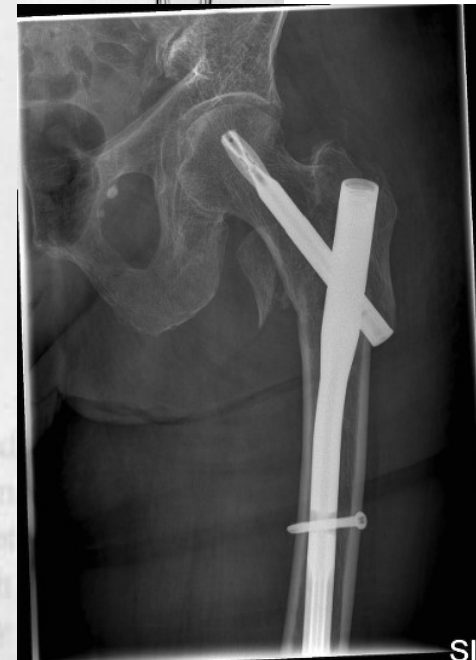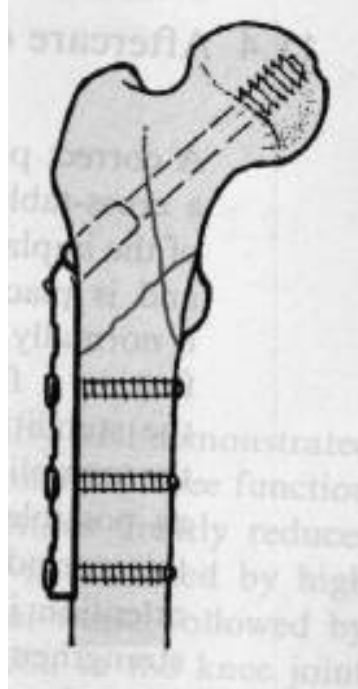
Lærleggssbrot – mjaðmaliður

- Trokanter; styttur og útsnúinn – mikil lærbólga



Collum
skrúfa
og plata

DHS=
Dynamic
Hip Screw



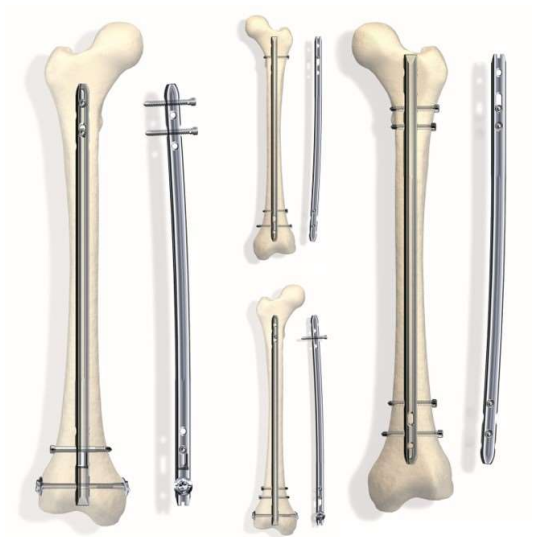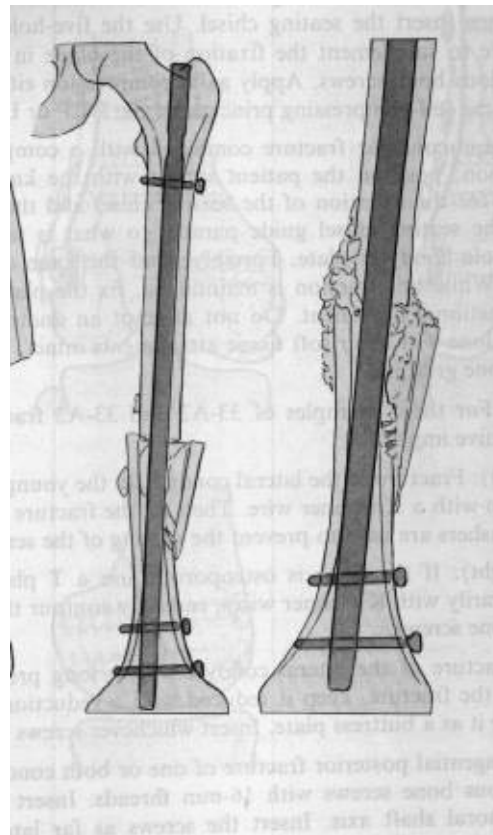
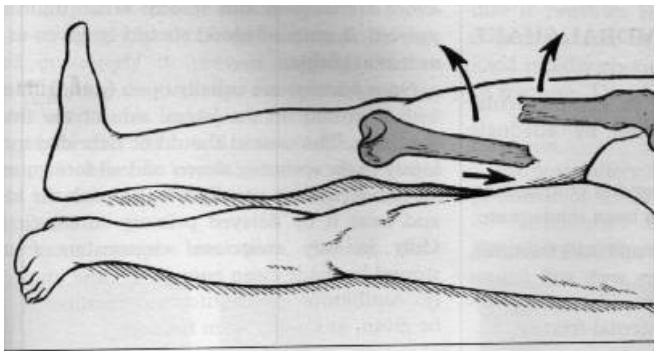
Collum
skrúfa og
mergnagli

Stuttur
Gammi

HJjr

Lærleggsbrot – skaftið

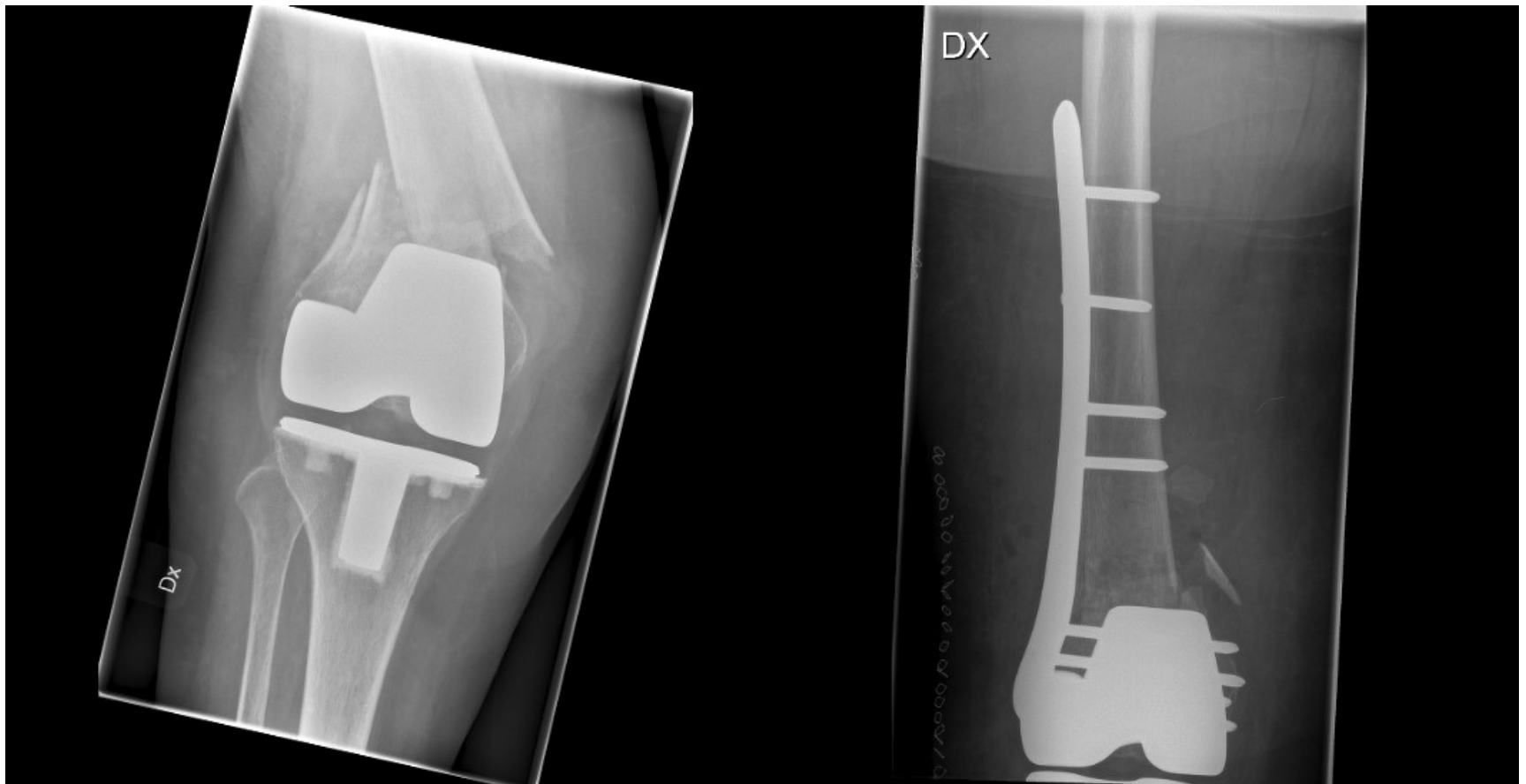
- Diafysan; styttur og útsnúinn; mjög mikil bólga



Mergnagli
(T2) og
þverskrúfur

Lærleggsbrot – hnéliður

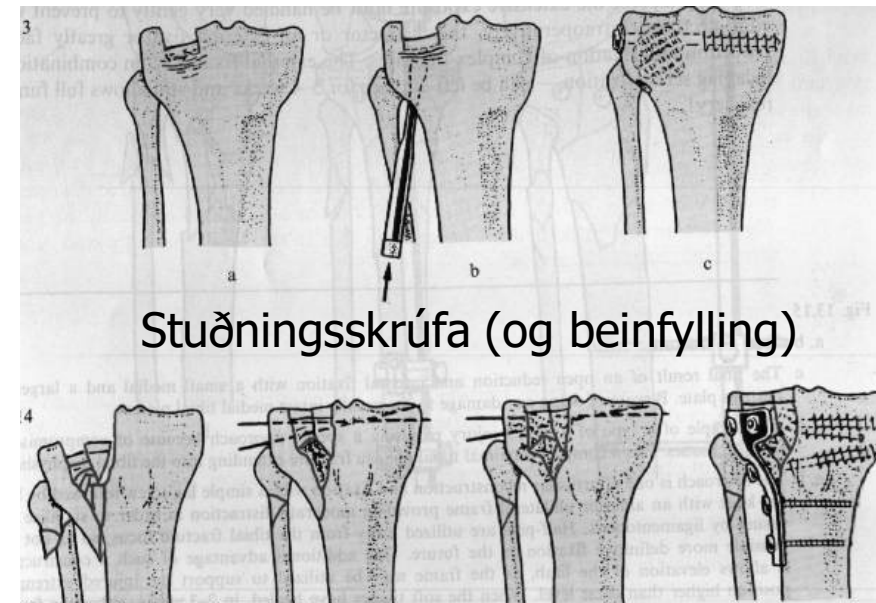
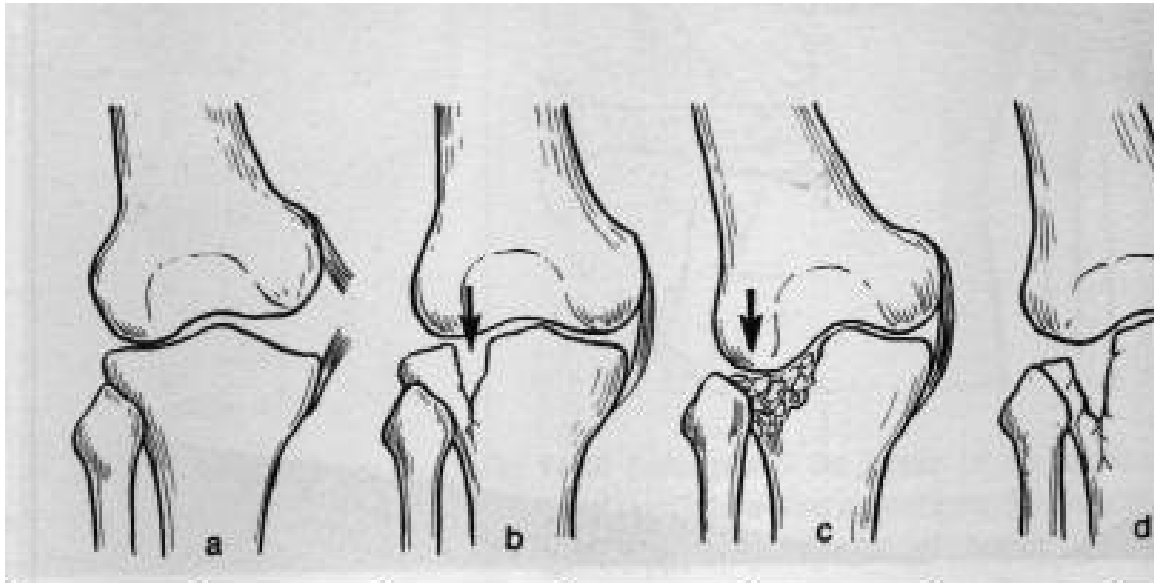
- Supracondylar („periprosthetic fx“ -grenndarbrot)



LISS eða NCB plata

Sköflungsbrot – hnéliður

- Lateral tibia condyll

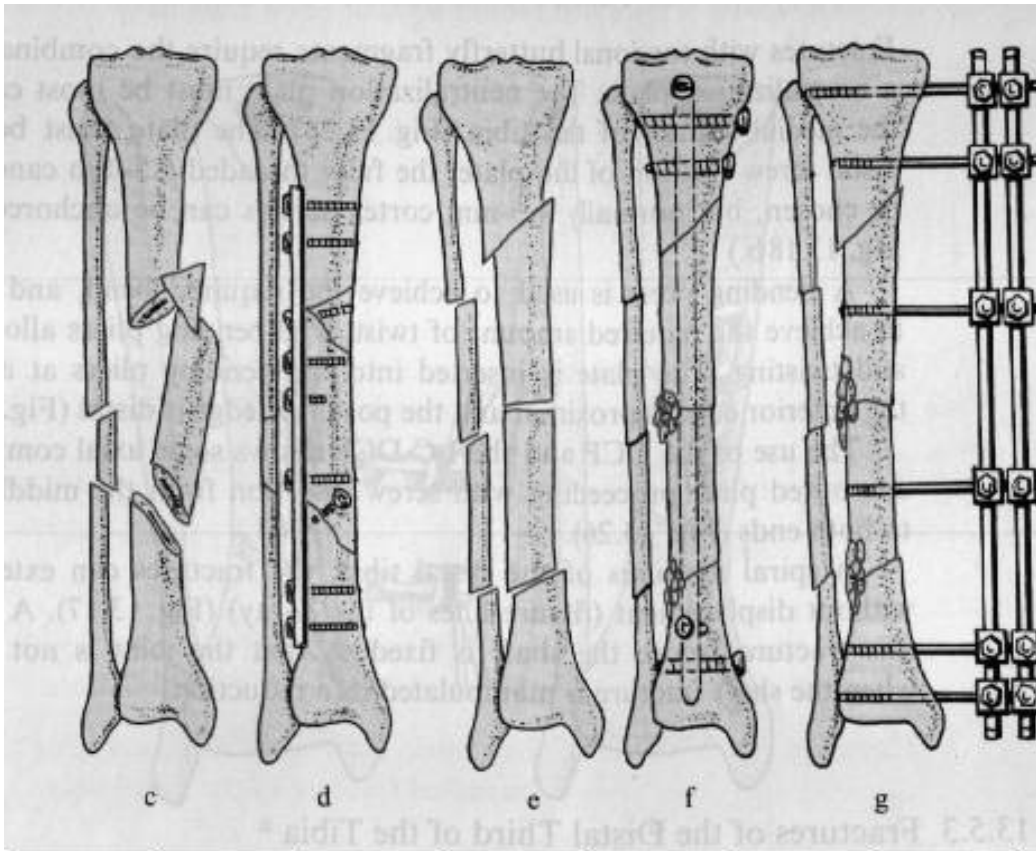


Stuðningsskrúfa (og beinfylling)

Stuðningsplata

Sköflungsbrot – skaftið

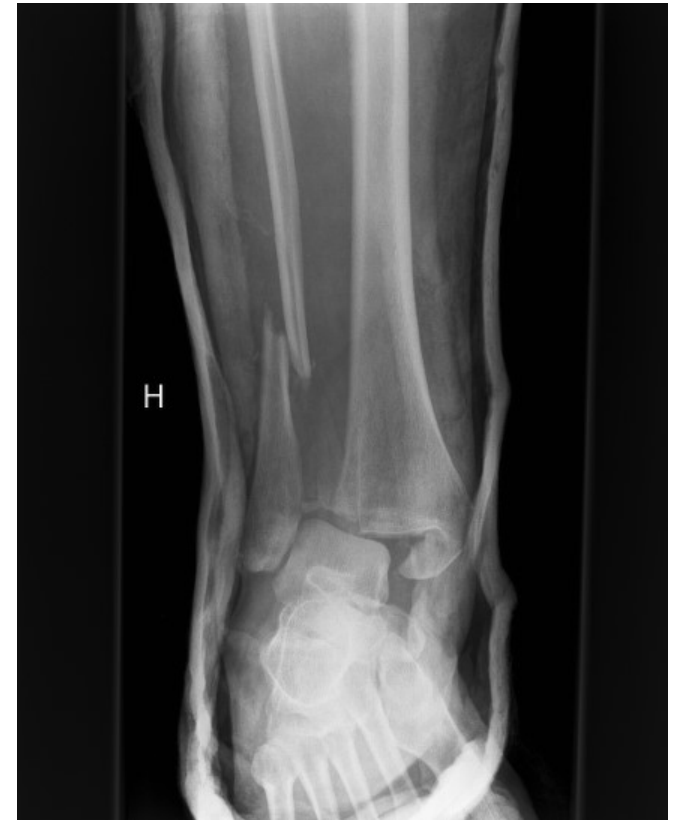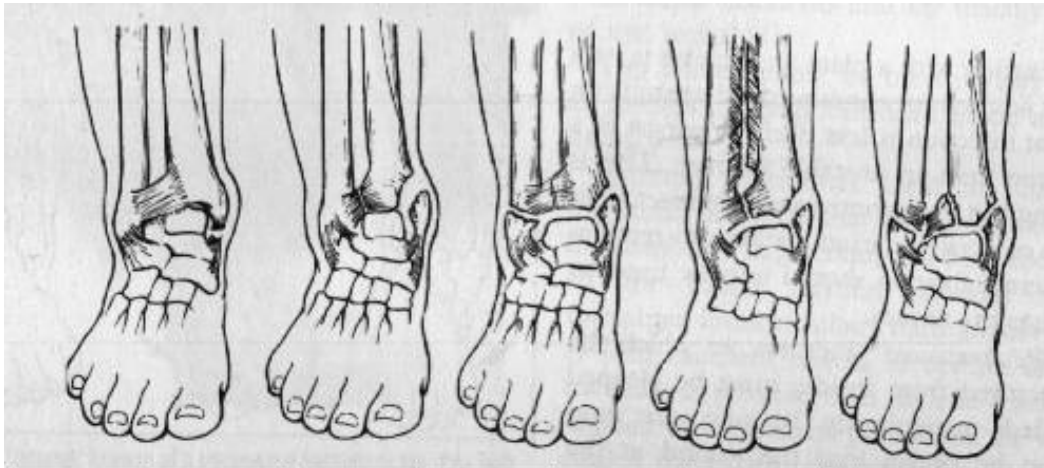
- Diafysan; varúð compartment



Plata (d), mergnagli (f), ytri festing - Hoffman (g)

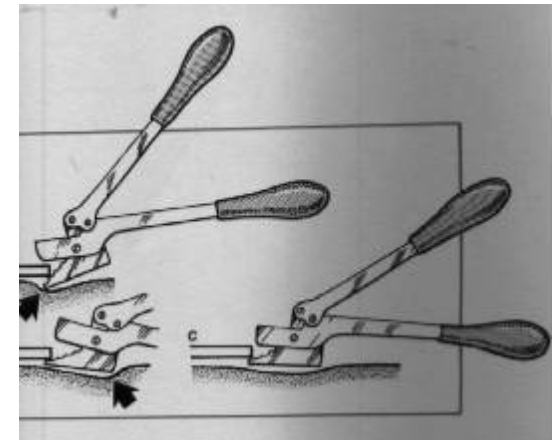
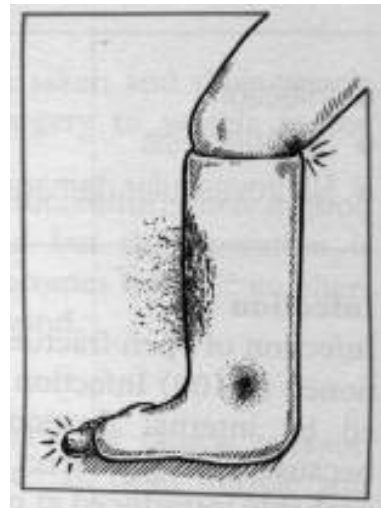
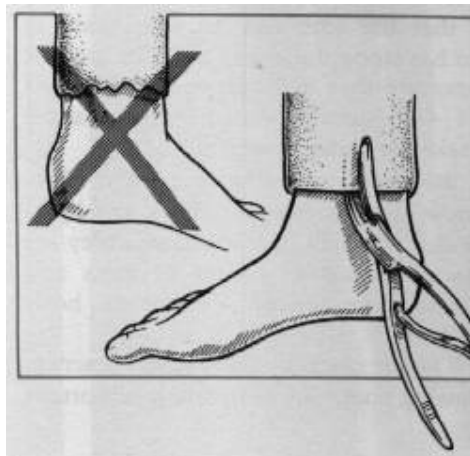
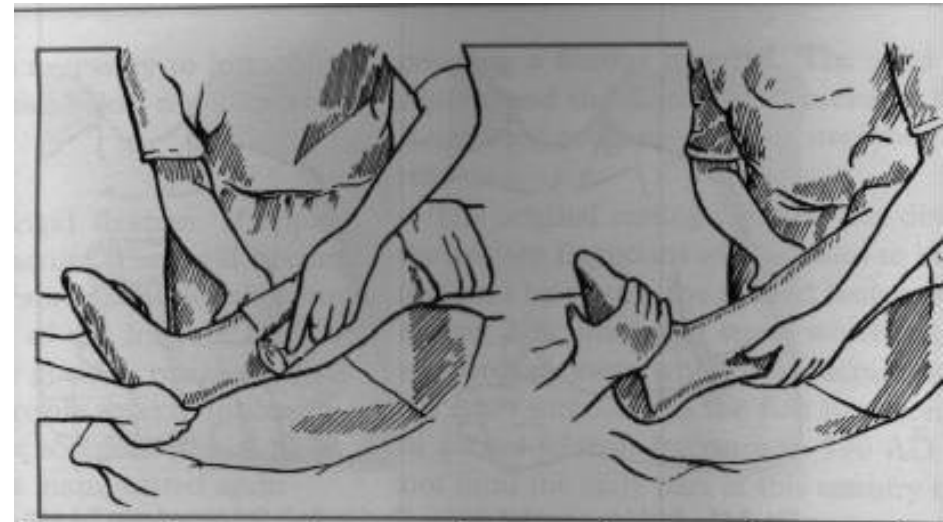
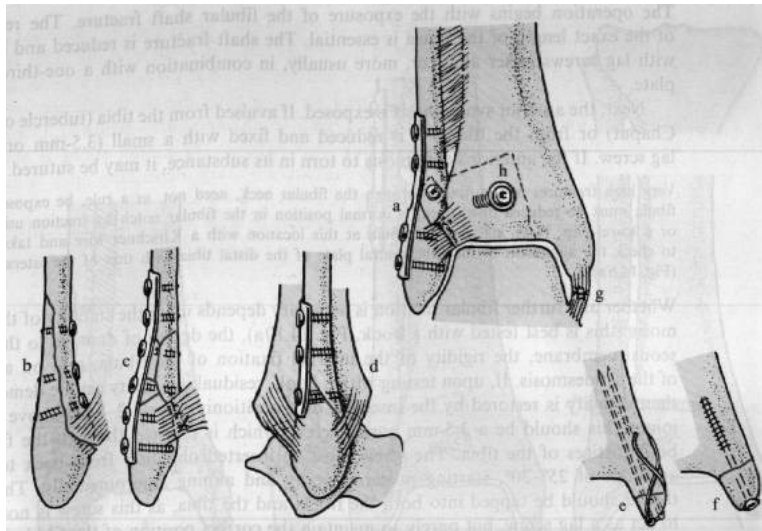
Ökklabrot – kúlurnar

- Lat mall; bi-mall; tri-mall; varúð liðhlaup



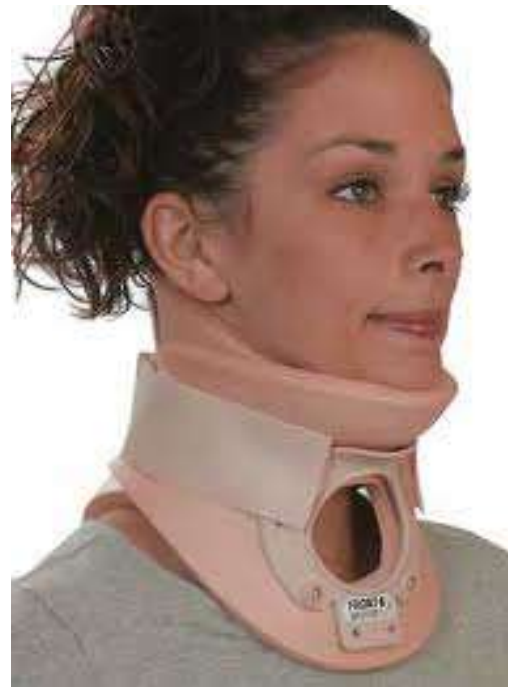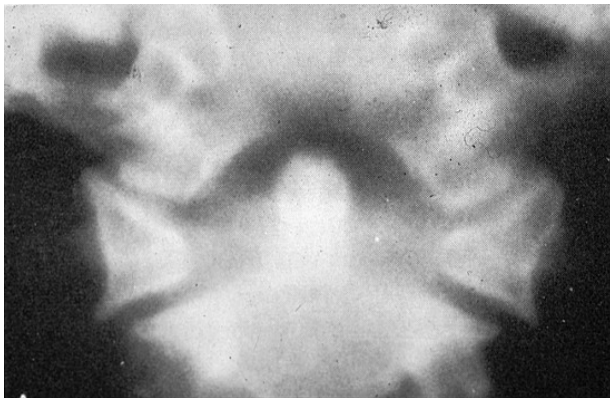
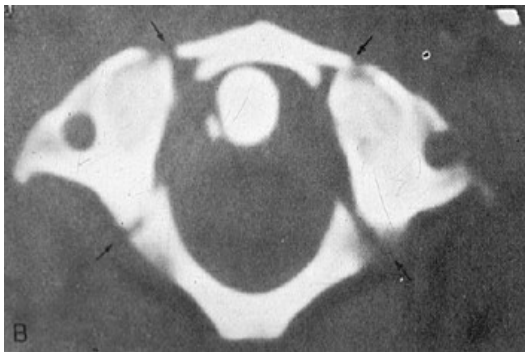
Ökklabrot – kúlurnar

- Skrúfur, plötur, pinnar, cerclage, gifs (varúð – þrengsli)

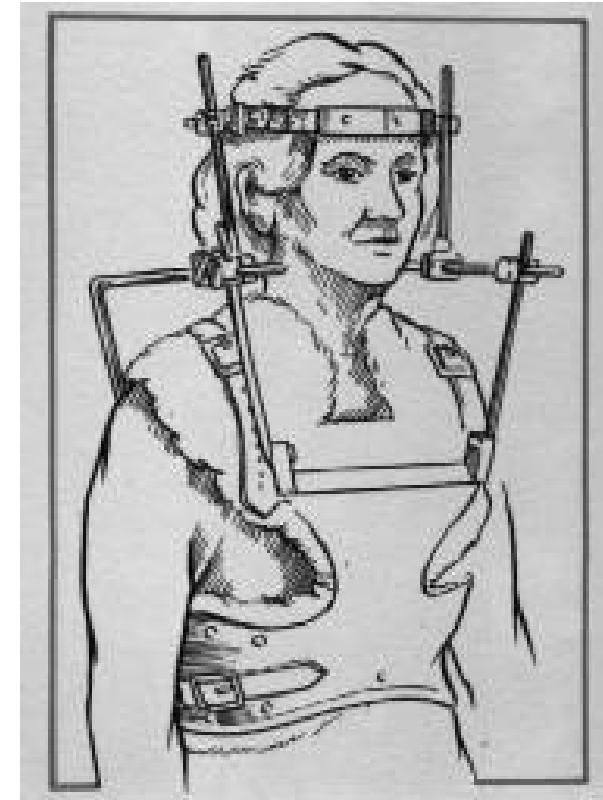


Hryggbrot – hálshryggur

- Efri: C1-Jefferson



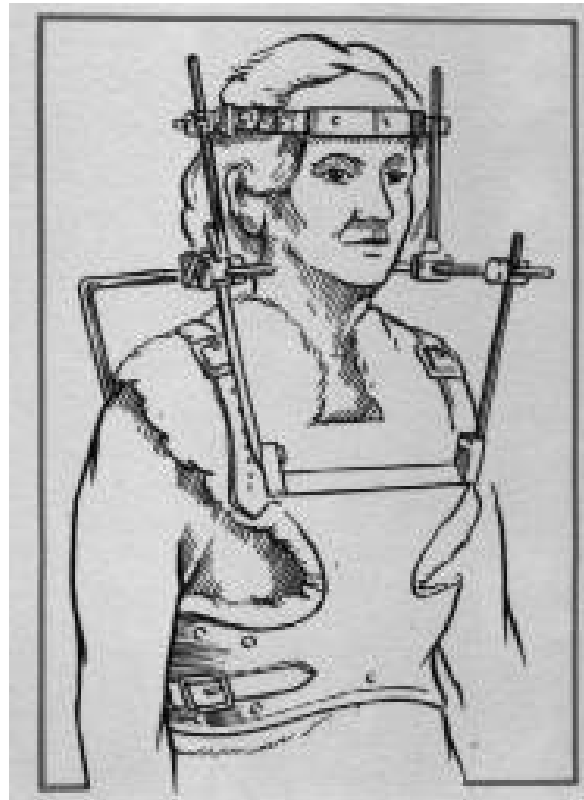
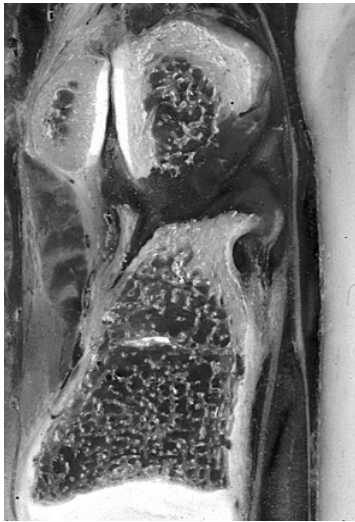
Philadelphia



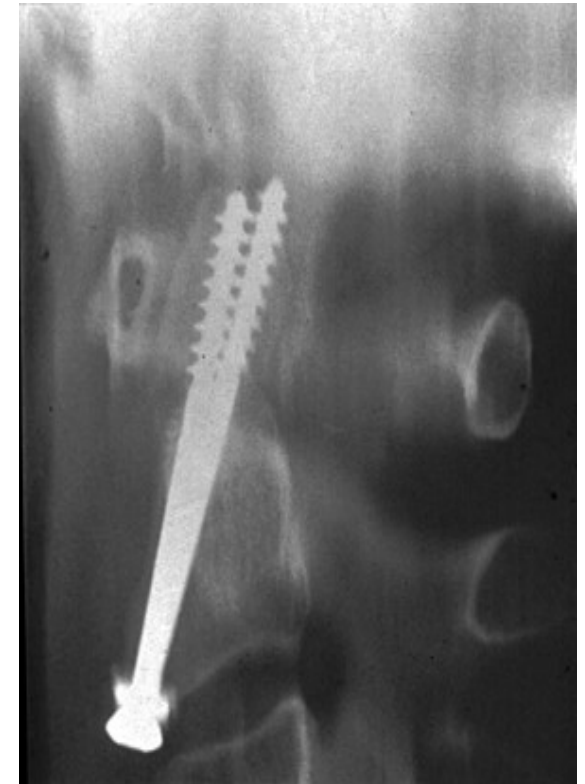Halovesti

Hryggbrot – hálshryggur

- Efri: C2- fremri (Dens)



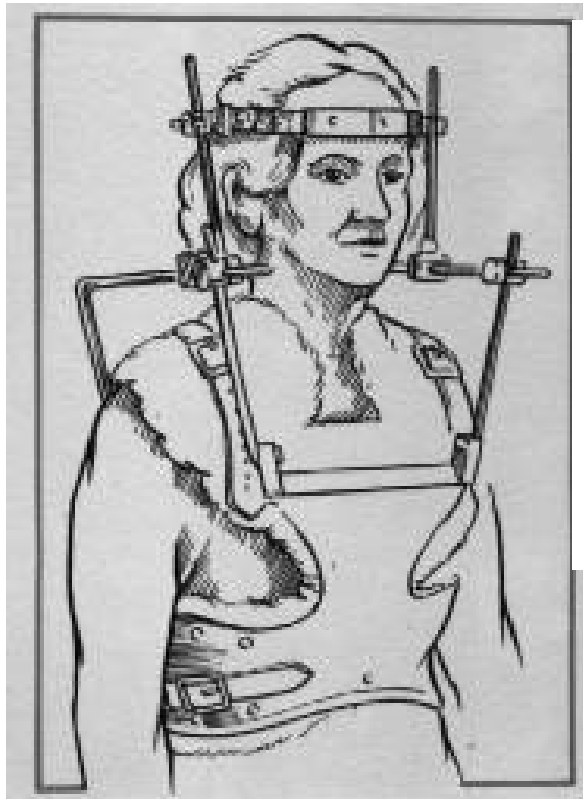
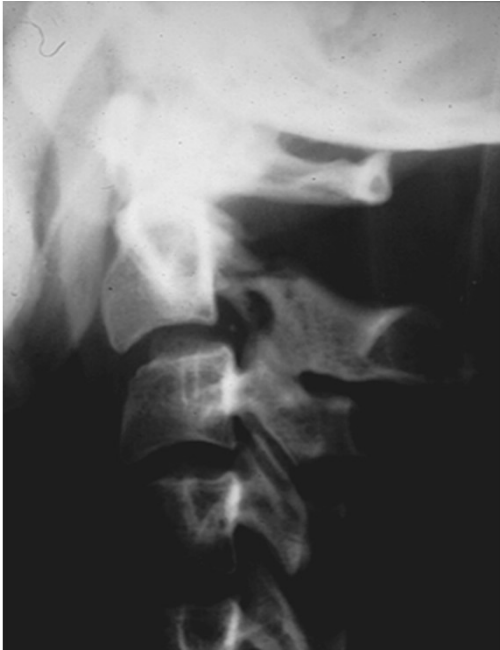Halo vesti



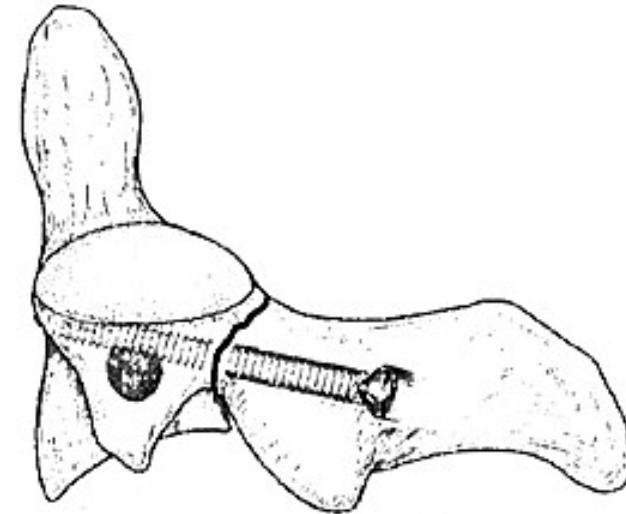
Böhlers skrúfur

Hryggbrot – hálshryggur

- Efri: C2- aftari (Hangmans)



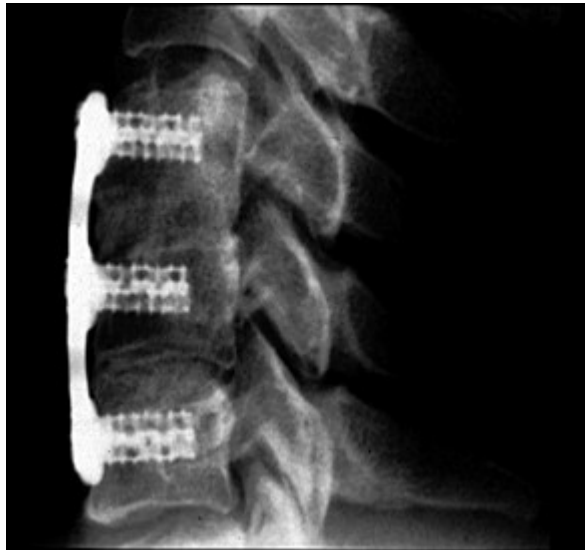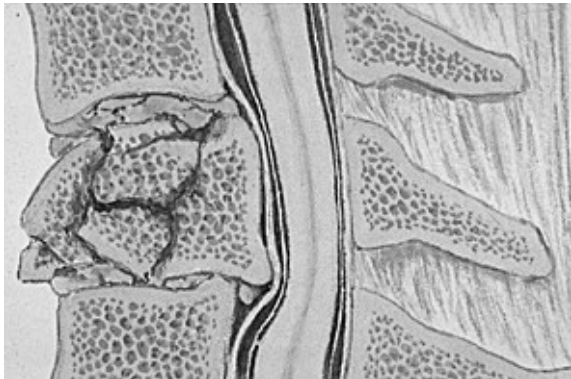
Halo vesti



Magerls skrúfur

Hryggbrot – hálshryggur

- Neðri: C3-C7 (hryggjarbolsbrot)



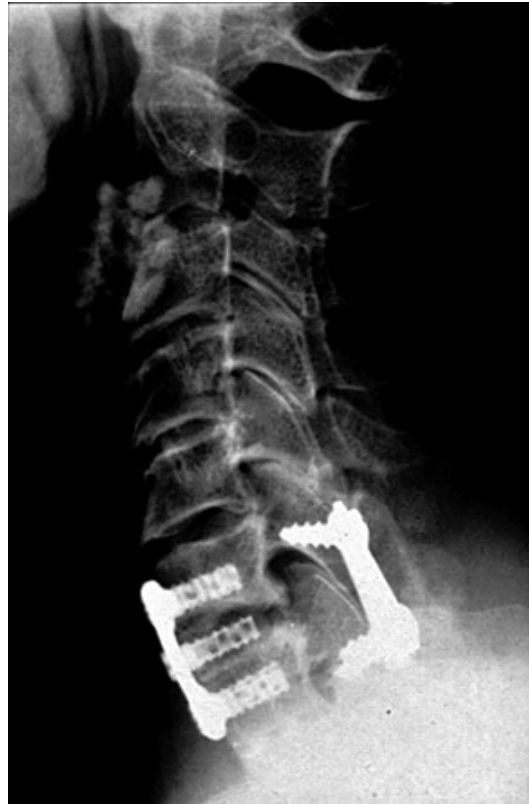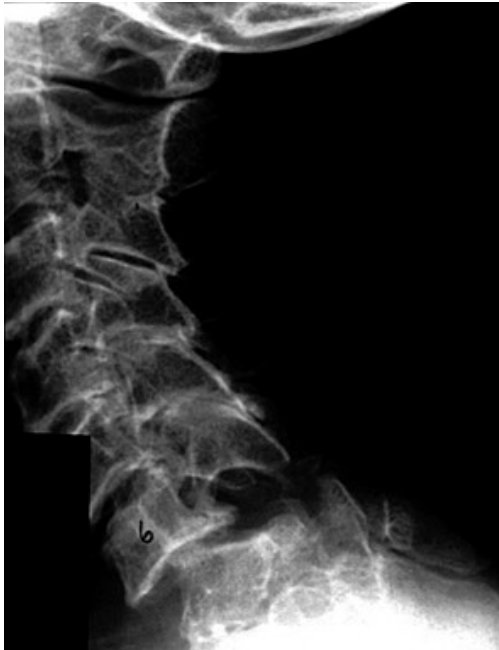Plata og skrúfur



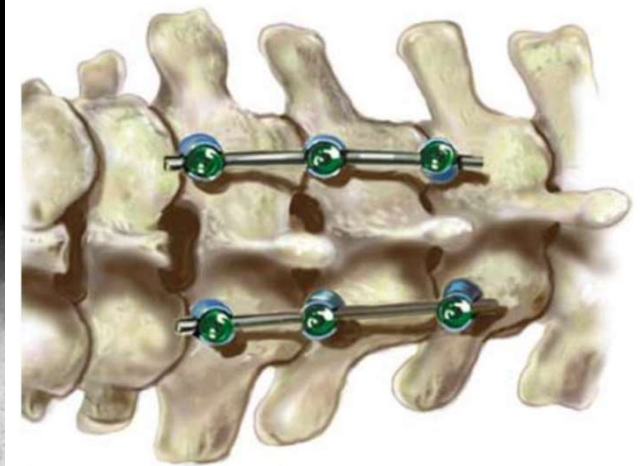
MaxAn plata og skrúfur

Hryggbrot – hálshryggur

- Neðri: C3-C7 (hálshryggjarliðhlaup)



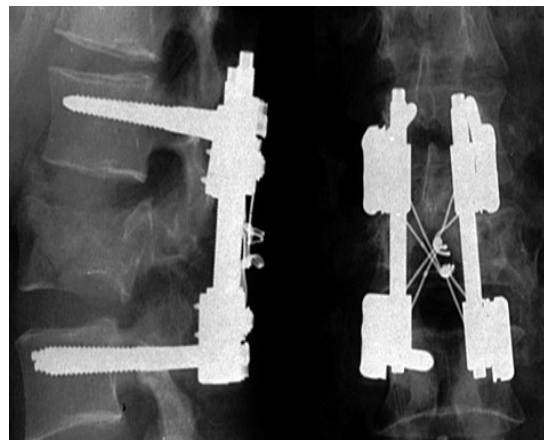
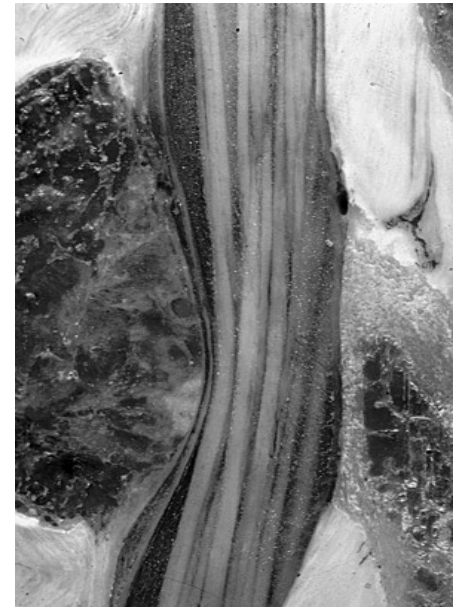
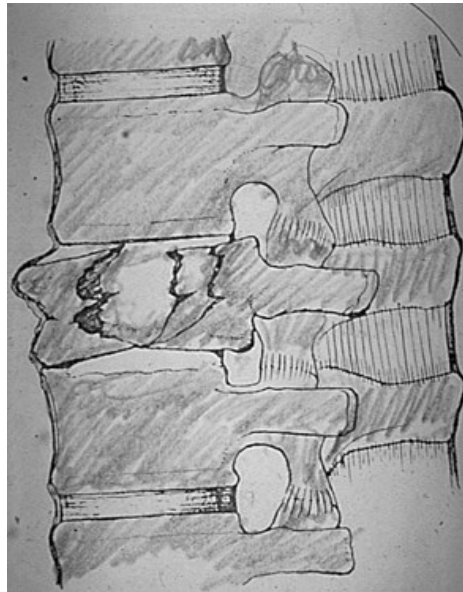

Fremri og aftari festing



Vertex stög og
skrúfur

Hryggbrot – brjóst/lendhryggur

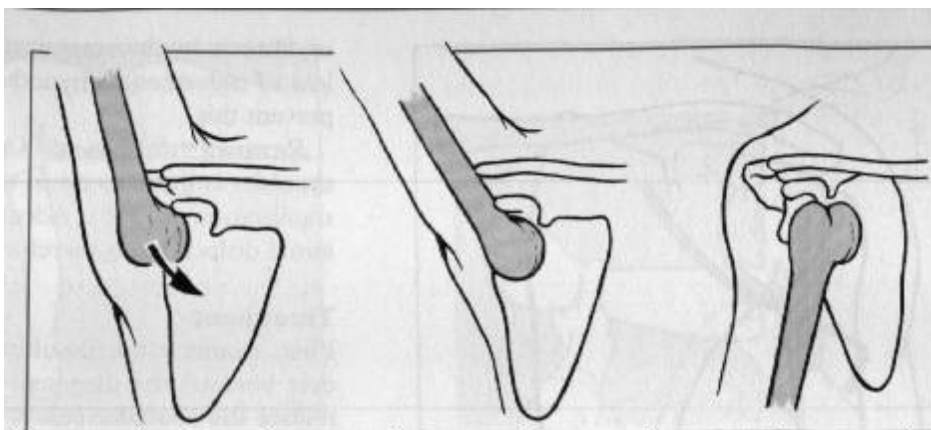
- TH12-LI-LII hryggjarbolsbrot



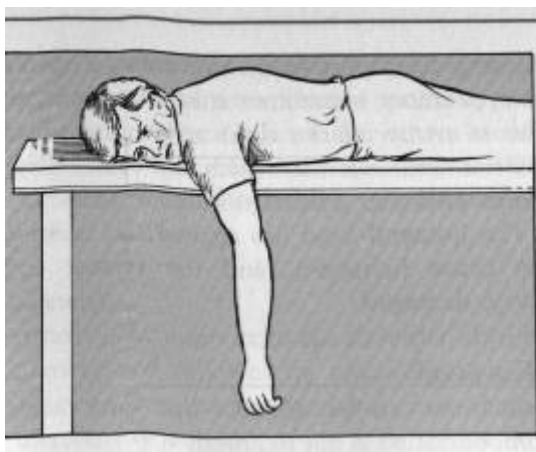
Dicks festibúnaður
(USS – Universal
Spine System)

Liðhlaup – öxl

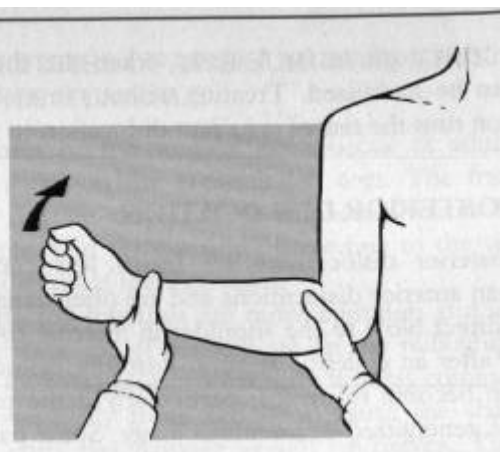
- Humeroglenoidal



Stimson
aðferð

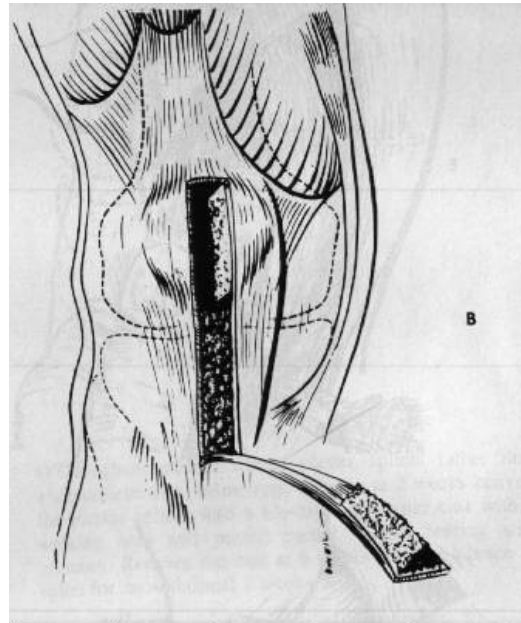
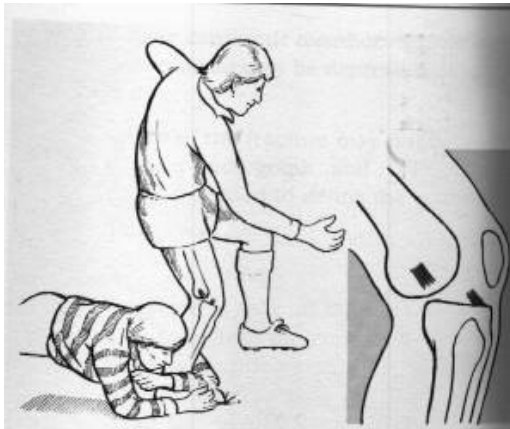

Kocher
aðferð



Liðbandaslit – hné

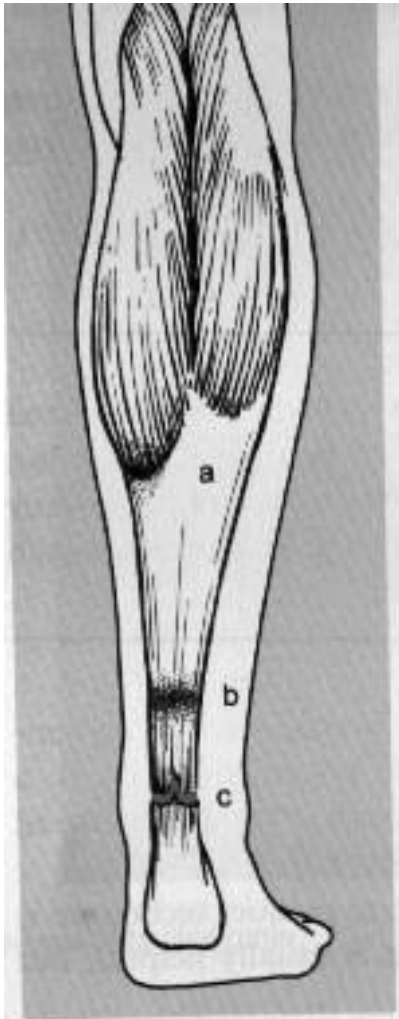
- Fremra krossbandið



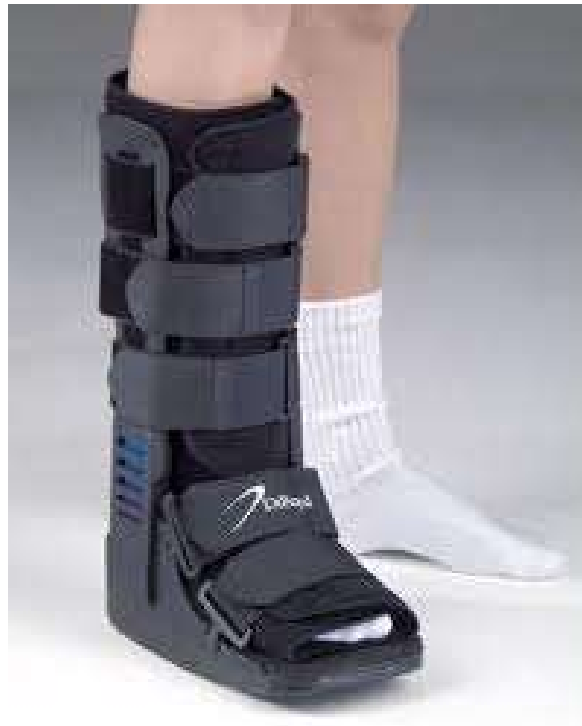Hægt að laga með ýmsum aðferðum:
Hér dæmi um hluta úr hnésin!

Sinaslit – hásin

- Achilles tendon



Ekki aðgerð: Walker



Aðgerð: sauma

