

BAKÁVERKAR

Mat - status Upphafsmæðferð Mæðferðaráætlun

Bogi Jónsson M.D. Ph.D. MBA

Uppsala Univ. Svíþjóð, 10 ár

McGill Univ. Kanada, 2 mán

Universitets Sykehus Nord Norge 9 ár



Mat á bakáverka

- ATLS
- Fyrir flutning
- Tryggja stabilitet fyrir hálshrygg – kragi
- Tryggja stabilitet fyrir bak –
vacuummadrass



Tíoni T-L brota

- 16% fractures between T1 and T10
- 52% between T11 and L1
- 32% between L1 and L5.

Reasons for TL-brota

- ◎ **Fall** **53%**
- ◎ **T-accidents** **37%**

Diagnos of TL-fractures

- ⦿ Interview/inspection
- ⦿ Palpation-palpate spinous processes
- ⦿ Neurologic evaluation
- ⦿ Conventional x-ray
- ⦿ CT skan
- ⦿ MRI

Some questions to be answered

- ⦿ Neurologic deficit
 - How much
- ⦿ Complete or incomplete nerve injury
- ⦿ Stable or instable spine fracture

Neuroradiologic investigation

- X-ray
- CT scan with reconstruction
- MRI

Pitfalls

- Spinal injuries are present at another location of the spine in 6% to 15% patients with thoracic and lumbar fractures.

Mat á bakáverka

- Áverkamekanismi
- Meðvitundarstig
- Lyfjæitrun
- Bakverkir, hvar
- Skyn- eða mótortruflanir



Bakáverkar

- ◎ Mikilvægt að komi fram
 - Hvenær var slysið
 - Distal status skráður



Mat á hálsáverkum með tilliti til rtg/ct--mri

The Canadian C-spine rule

- ⦿ High risk faktorar
- ⦿ Low risk faktorar




Mat á hálsáverka.

The Canadian C-spine rule

⦿ High risk faktorar

- >65 ára
- Fall 1 meter eða meira. Umferðaslys, stinga sér til sunds o.s. frv.
- Dofi eða kraftminnkun í efri útlimum.



Háls hrygggsáverkar

- Með nevrologiu
 - þá hafa samband við heila og taugaskurðlækna
- Án nevrologiu
 - þá hafa samband við vakthafandi bæklunarlækni
- Þessir aðilar eru síðan ábyrgir fyrir meðferðinni og kveða á um hvort eða hvenær aðgerðar er þörf en ekki þarf að operera öll óstabil brot



Hálshrygggsáverkar

Anatómískt greinum við á milli efri og neðri hálshrygg

- Efri hálshryggur C0 – C2
- Neðri hálshryggur C2 - C7



Áverkar í efri háls hrygg

C0-C1 brot- ***Occypitalcondylfx***

C1 brot, atlas disruptionsjon ***Jefferssonfx, >7,5***

C2 brot

– ***Dens brot og Hangmanbrot***

- Þessi brot eru algengust hjá börnum og eldri (>60ár)
- 70% af hálsbrotum hjá 60 ára og eldri
- Minor trauma sem orsök hjá eldri einstaklingum en major trauma hjá yngri einstaklingum.



Áverkar í efri háls hrygg

C2- brot

Dens brot – Anderson and D'Alonzo

**Hafa aukist gríðarlega með hækkandi aldri.
Flest má meðhöndla með hálskraga.**




Hangmansbrot – Effendi

Type I <3mm dislocation

Type 2 > 3mm dislocation

->instabíl

**Type III rof í pars og facettuliða-
dislocation ->instabíl**



NEÐRI HÁLSHRYGGUR

Subaxial cervical spine injury classification

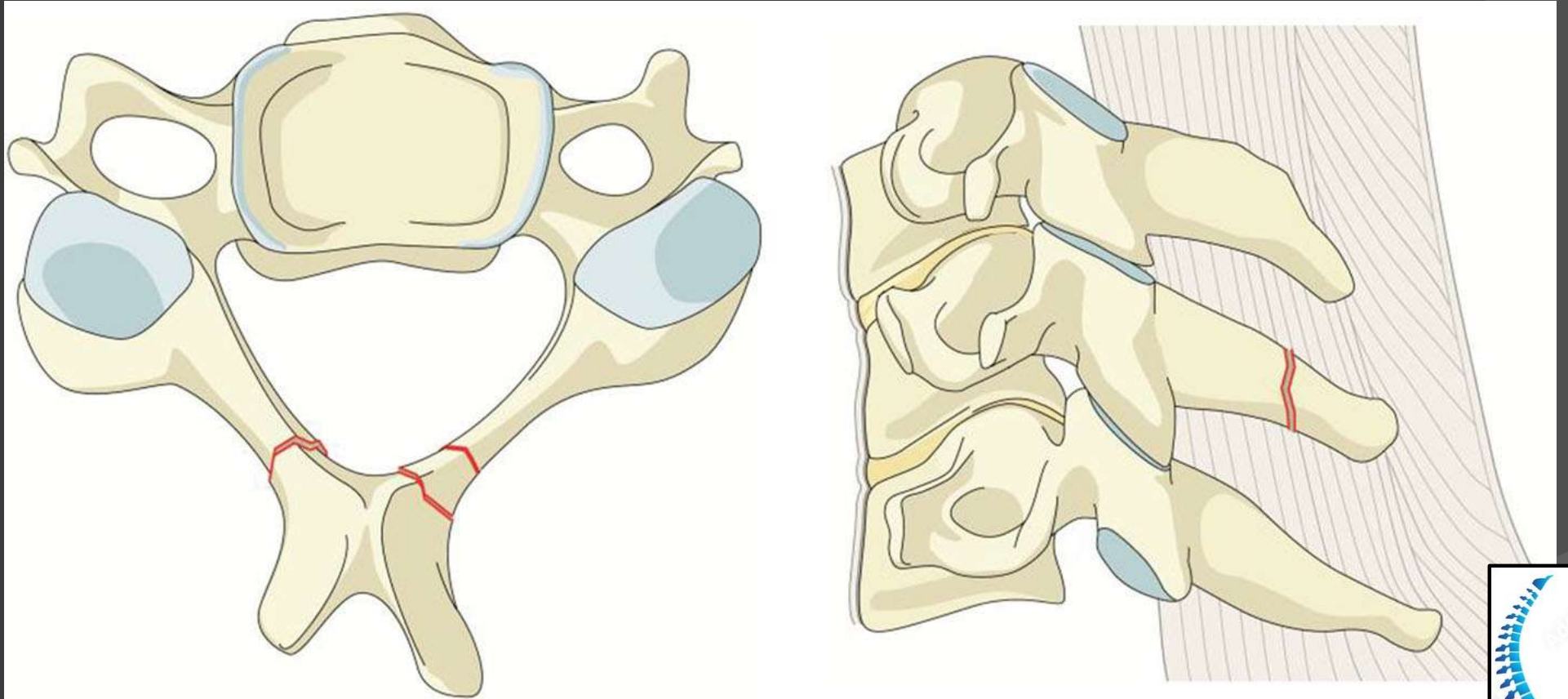


Typa A brot

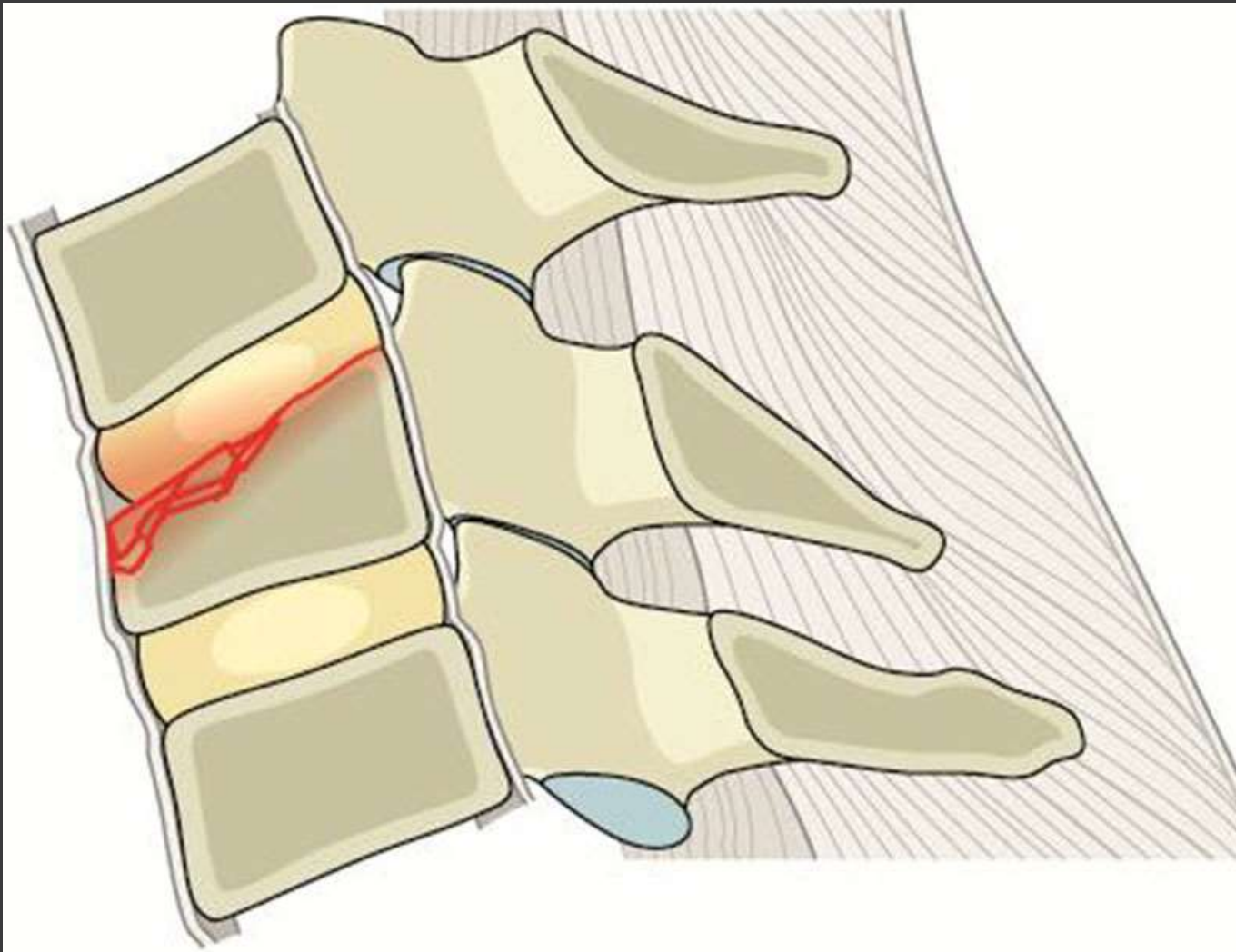
- Skipt i 5 undirflokkka
- A1,A2,A3,A4 og A5



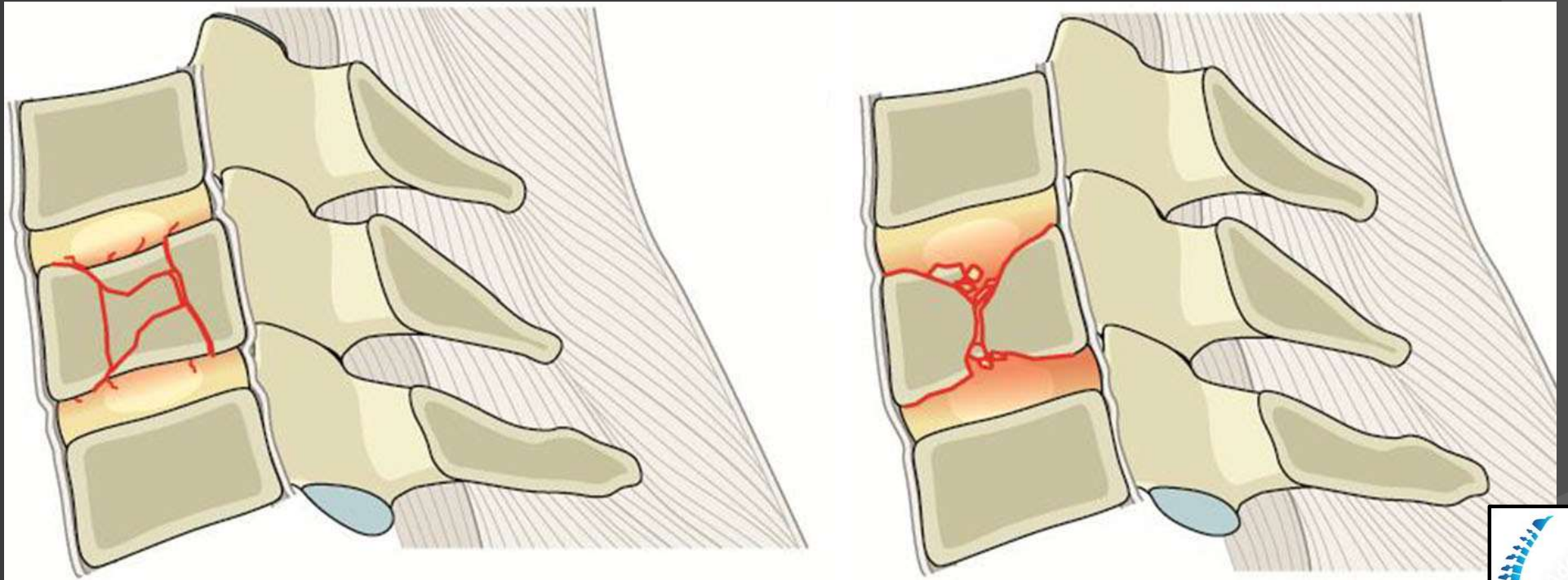
A0 brot




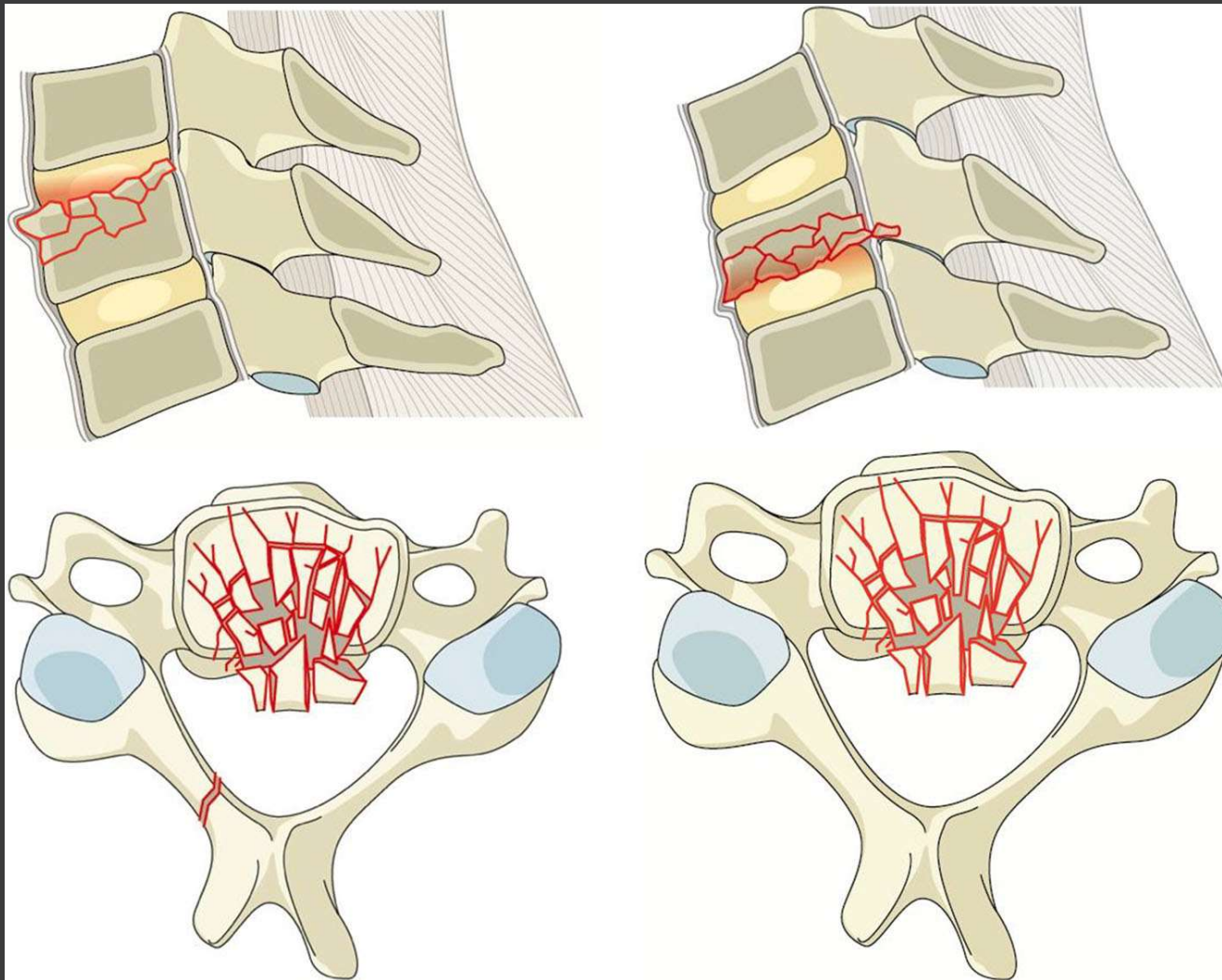
A1 kompresjonsbrot



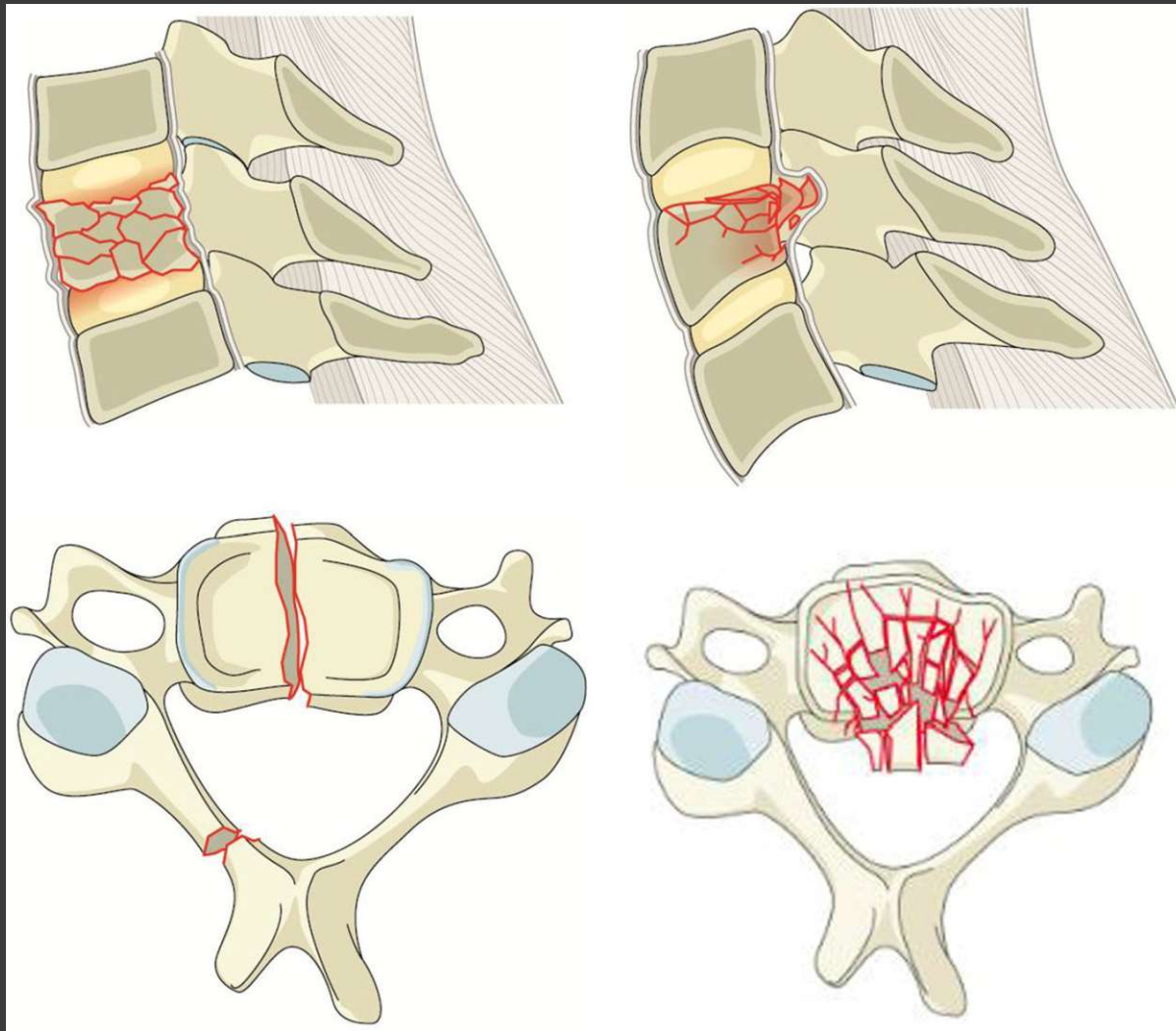
A2 kompressionsbrot



A3 kompresjonsbrot



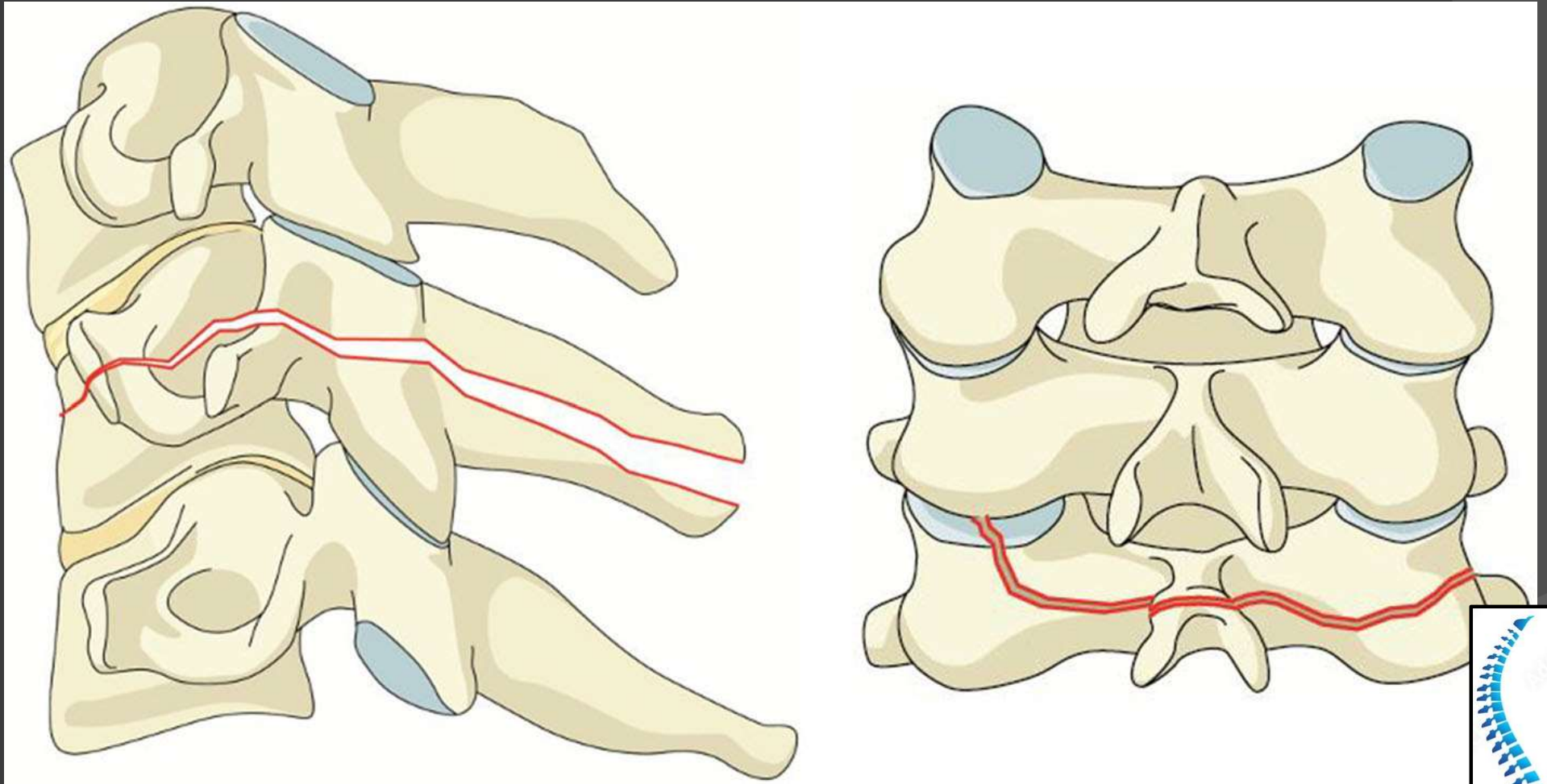
A4 kompresjonsbrot




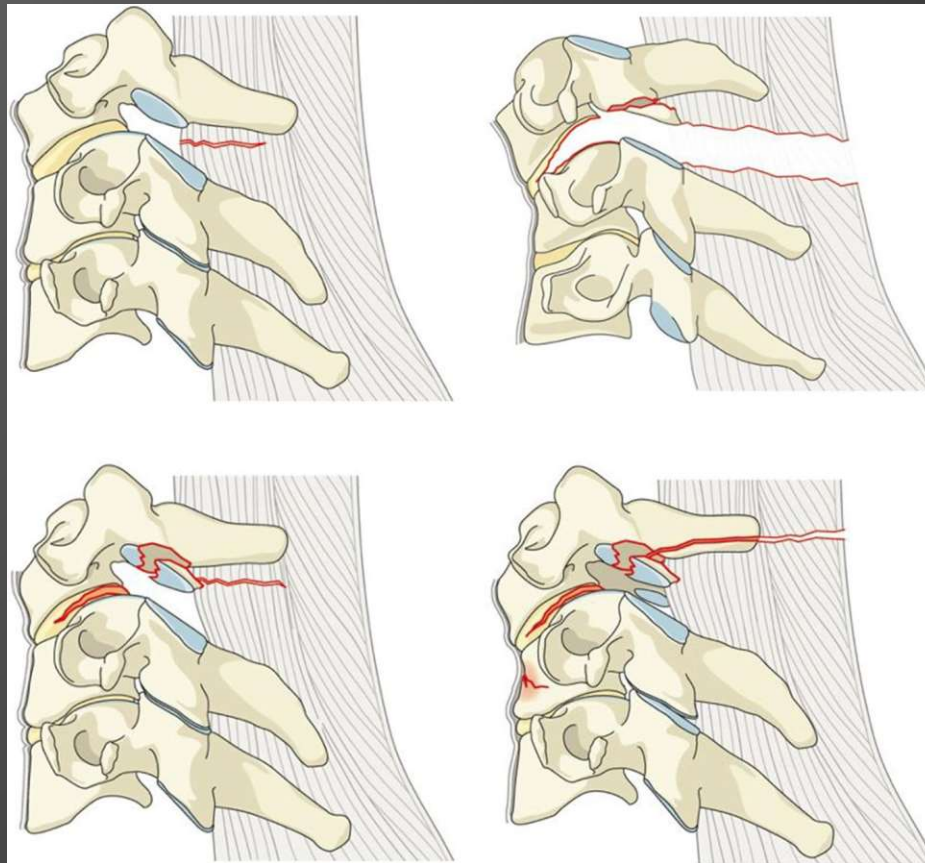
Typa B skađar



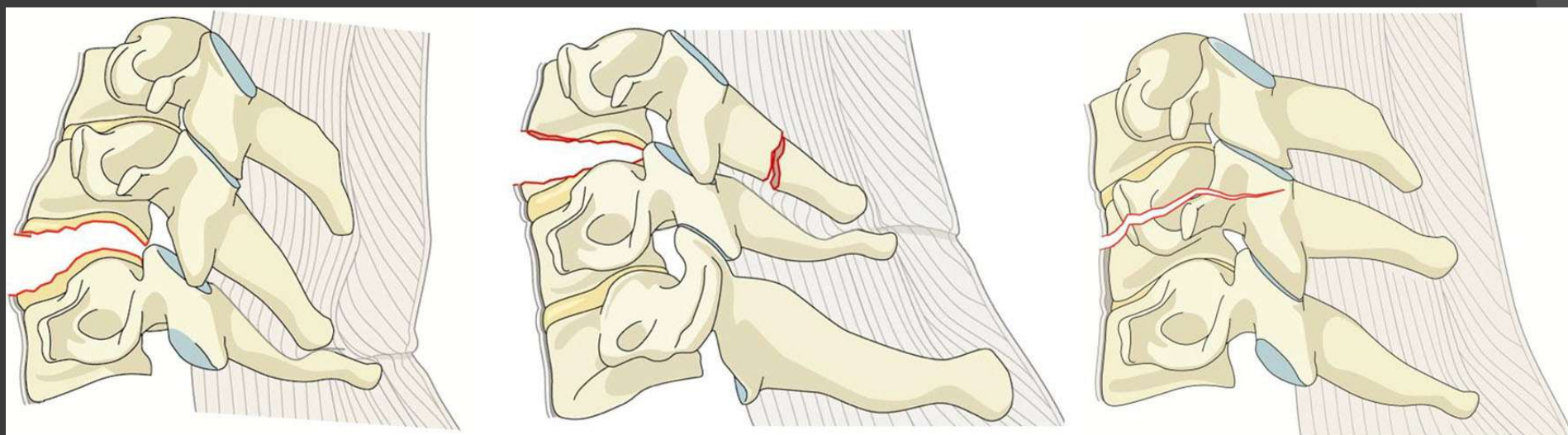
B1 áverki



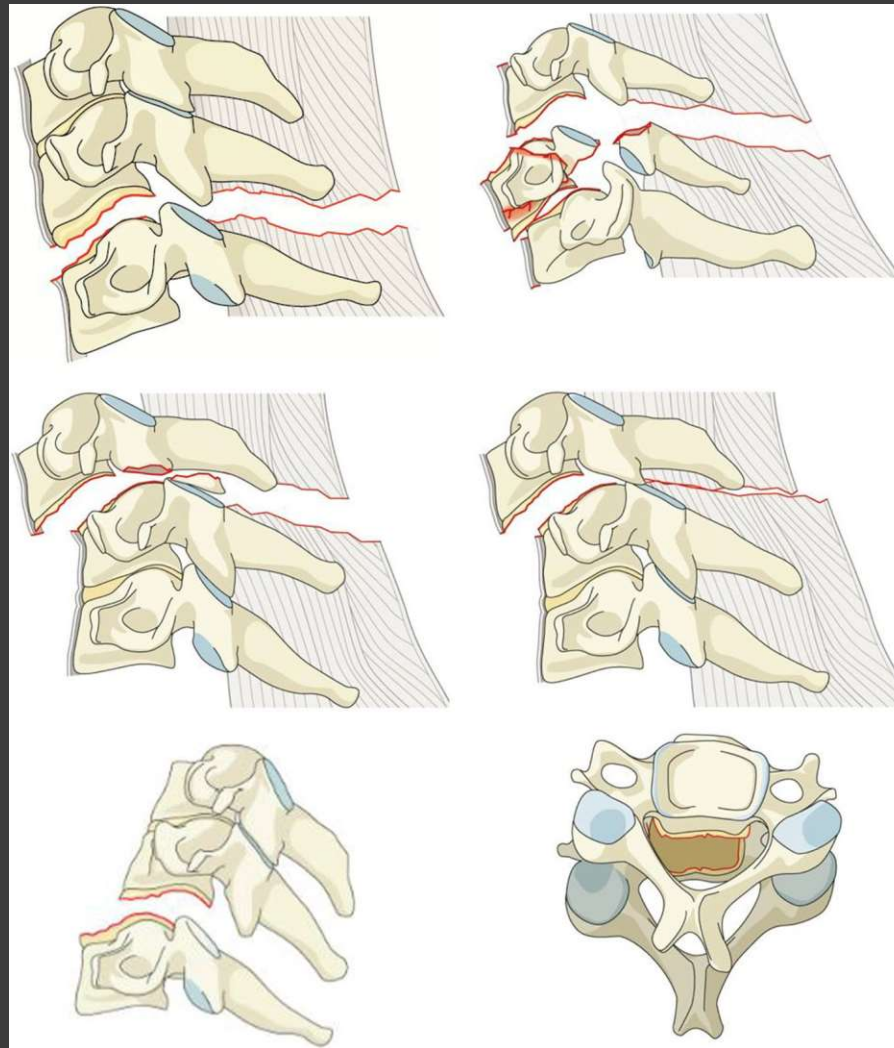
B2 ÁVERKI



B3- áverki

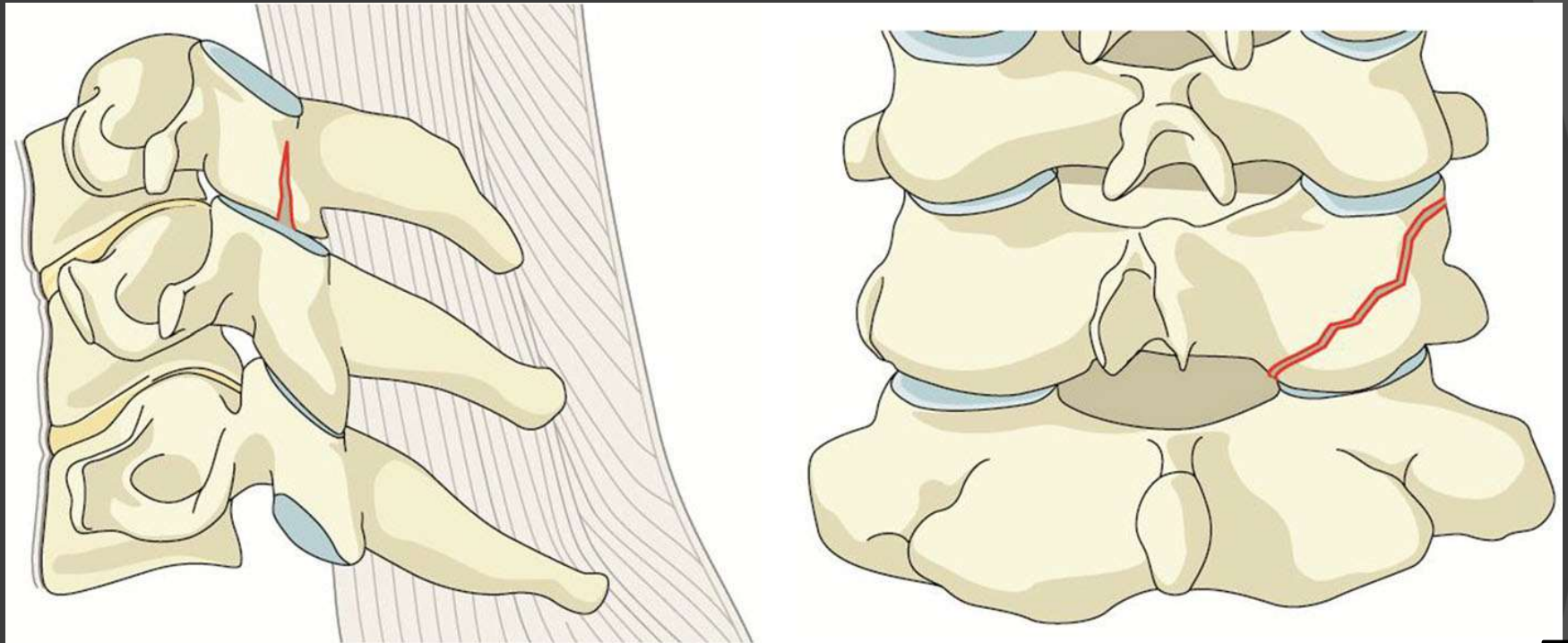


C- áverki



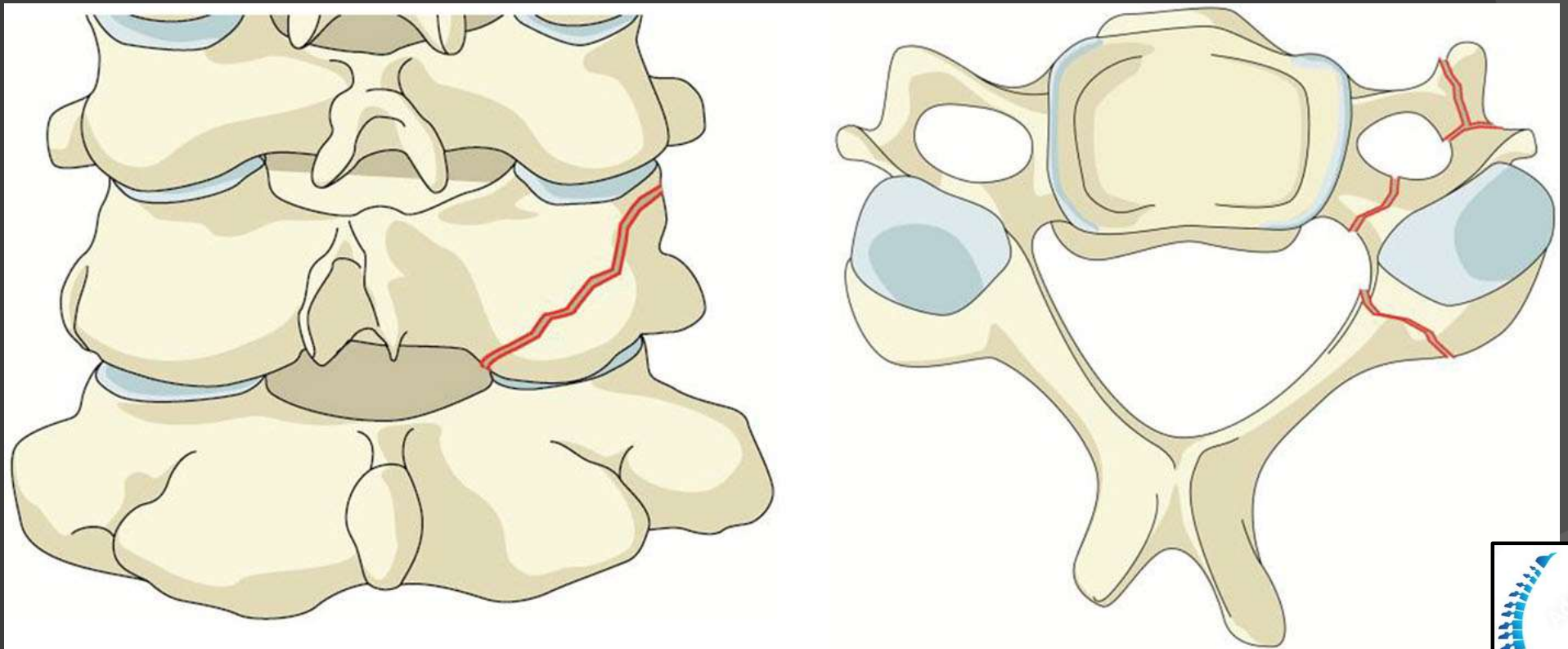
F1-áverki

Ódiloseruð facettuliðafraktura



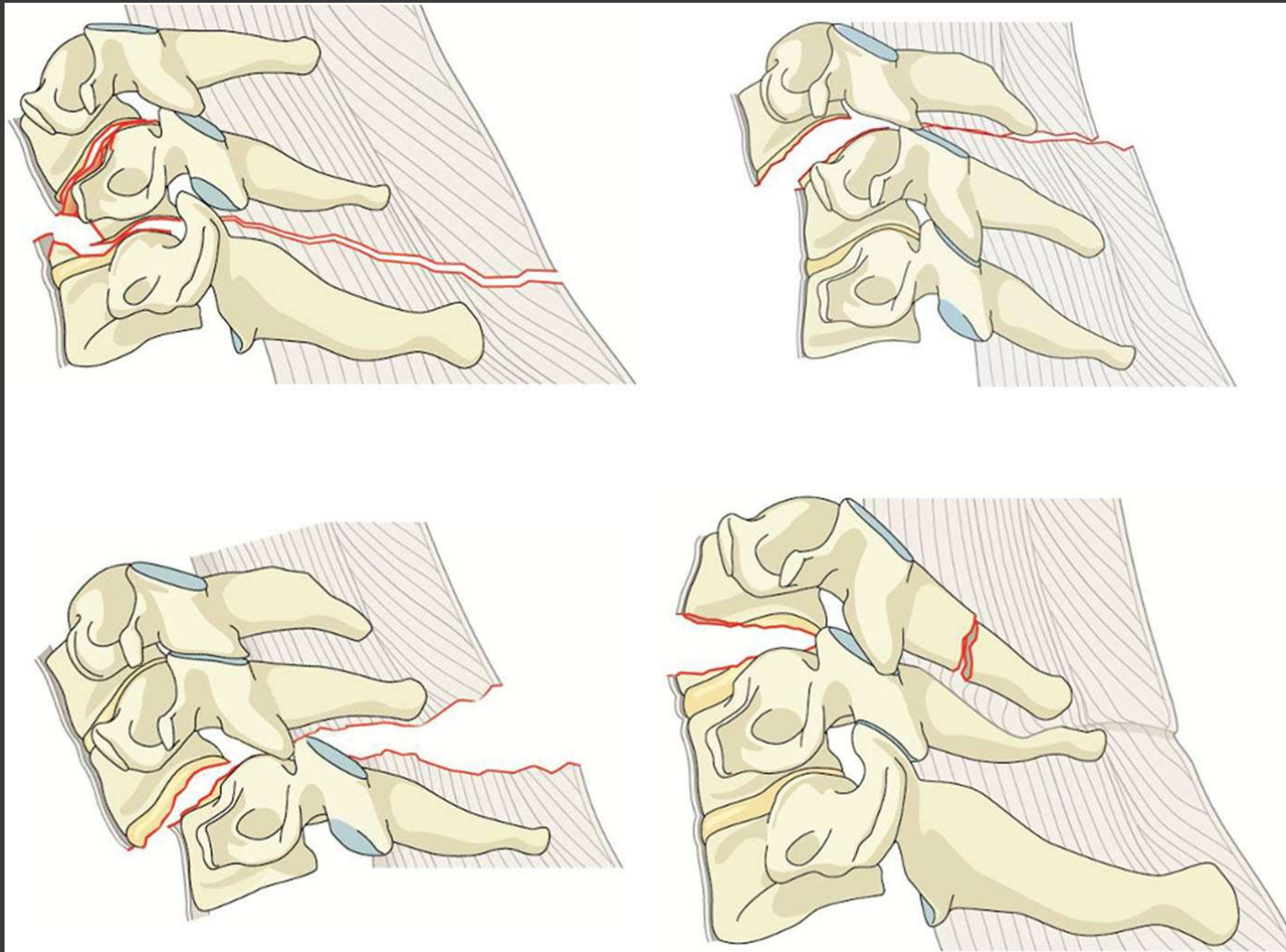
F3-áverki

Floating lateral mass




F4-áverki

Patologisk subluksasjon



Subaxial Injury Classification- SLIC kerfið

- ◎ Morfologia:
 - Ekkert abnormalitet 0
 - Samfall 1
 - Burst +1=2
 - Distraction,hyperextension 3
 - Rotasjon/translasjon7tear drop 4
- ◎ DLC
 - Intact 0
 - Aukið interspinal bil 1
 - Disruption, aukið discbil,kyfosa 2
- ◎ Taugastatus
 - Intact 0
 - Taugarótaráverki 1
 - Komplett mænuskaði 2
 - Inkomplett taugaskaði 3
 - Vaxandi taugaeinkenni +1



Konservativ vs kirurgisk meðferð

- Ef SLIC severity score er = 4 eða <4 (1-3)
 - -> konservative meðferð
- Ef SLIC severity score er = eða >5
 - -> íhuga kirurgíska meðferð



THORACOLUMBAR SPINE CLASSIFICATION



Tíoni T-L brota

- ◎ 16% fractures between T1 and T10
- ◎ 52% between T11 and L1
- ◎ 32% between L1 and L5.

Reasons for TL-brota

- ◎ **Fall** **53%**
- ◎ **T-accidents** **37%**

Diagnos of TL-fractures

- ⦿ Interview/inspection
- ⦿ Palpation-palpate spinous processes
- ⦿ Neurologic evaluation
- ⦿ Conventional x-ray
- ⦿ CT skan
- ⦿ MRI

Some questions to be answered

- ⦿ Neurologic deficit
 - How much
- ⦿ Complete or incomplete nerve injury
- ⦿ Stable or instable spine fracture

Neuroradiologic investigation

- X-ray
- CT scan with reconstruction
- MRI

Pitfalls

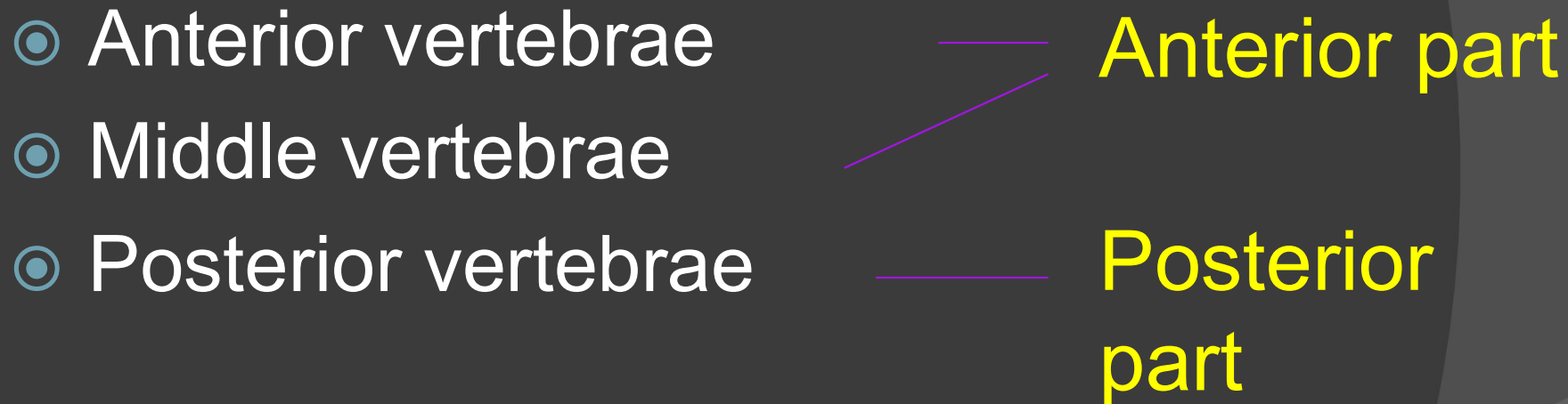
- Spinal injuries are present at another location of the spine in 6% to 15% patients with thoracic and lumbar fractures.

The aim of fracture treatment is:

- ⦿ Reestablish the anatomy by reducing the fracture
- ⦿ Stable fixation
- ⦿ Atraumatic surgical intervention
- ⦿ Rehabilitation as soon as possible

Stable/Unstable spinal fracture

Dividing the spine into three parts

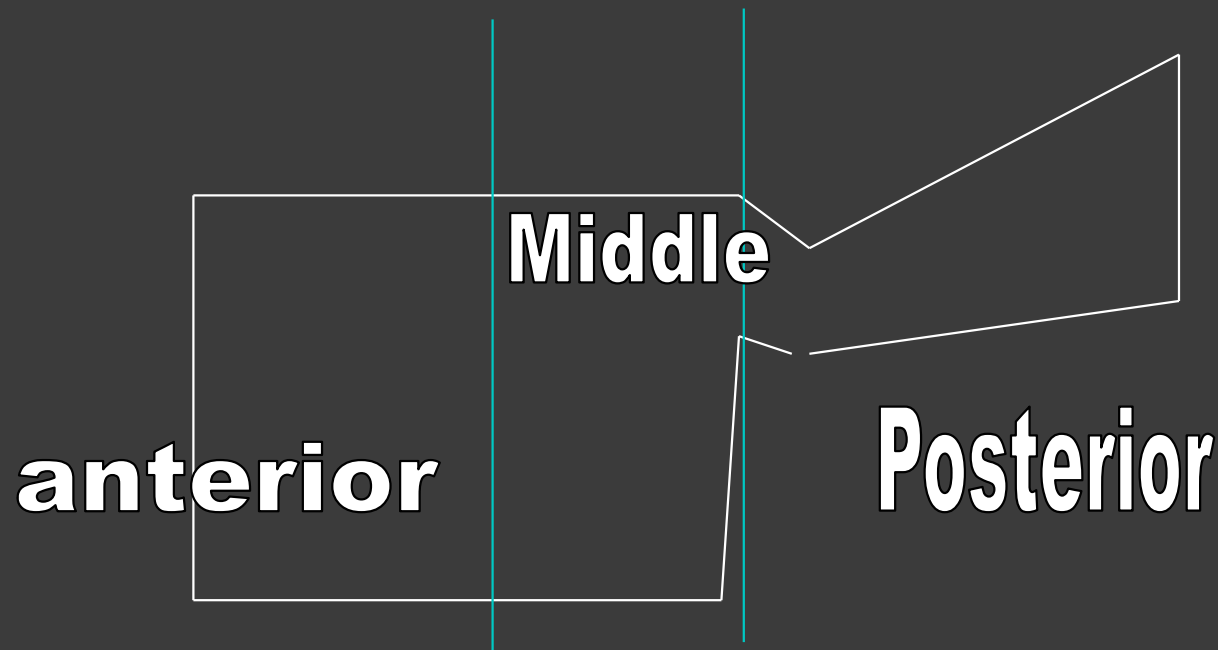
- Anterior vertebrae
 - Middle vertebrae
 - Posterior vertebrae
- Anterior part
- Posterior part
- 

If 2 out of 3 parts of the spine is broken then there is an instable fracture

Stability of fractures

- Diagnosis with CT-scan

2 or more columns broken = unstable fractures



Unstable fractures

- We stabilize operatively all unstable fractures of the spine

Classification of thoracolumbar fractures

AO-classification

- Compression fx _____ Type A
 - Burst fx _____
 - Flexion-distraction injury _____ Type B
 - Traumatic spondylolisthesis _____ Type C
 - Rotations-Translation injury _____
-
- _____

Aðgerðarábendingar

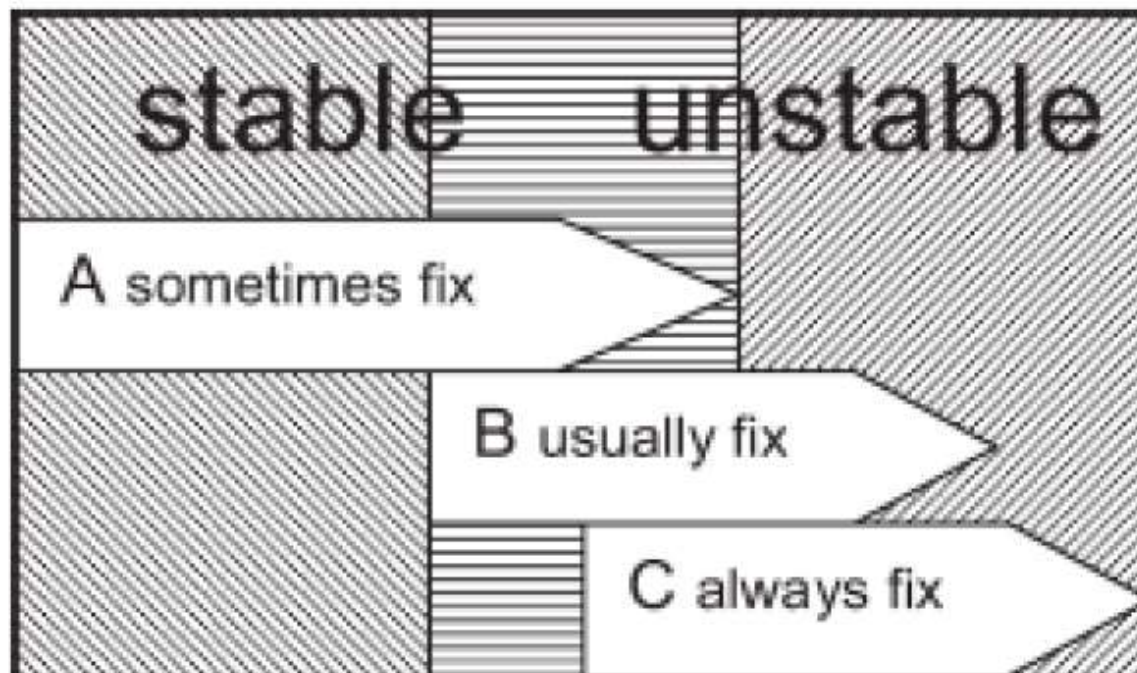


Fig 5: Schematic representation of stability of thoracolumbar fractures according to AO classification and indications for surgical stabilization.

Type-A

Compressions fractures

Vertebral body compression

- ① 1. Impaction on an endplate
- ② 2. Wedge fracture
- ③ 3. Split fractures
- ④ 4. Pincer fracture
- ⑤ 5. Burst fractures

Type-B

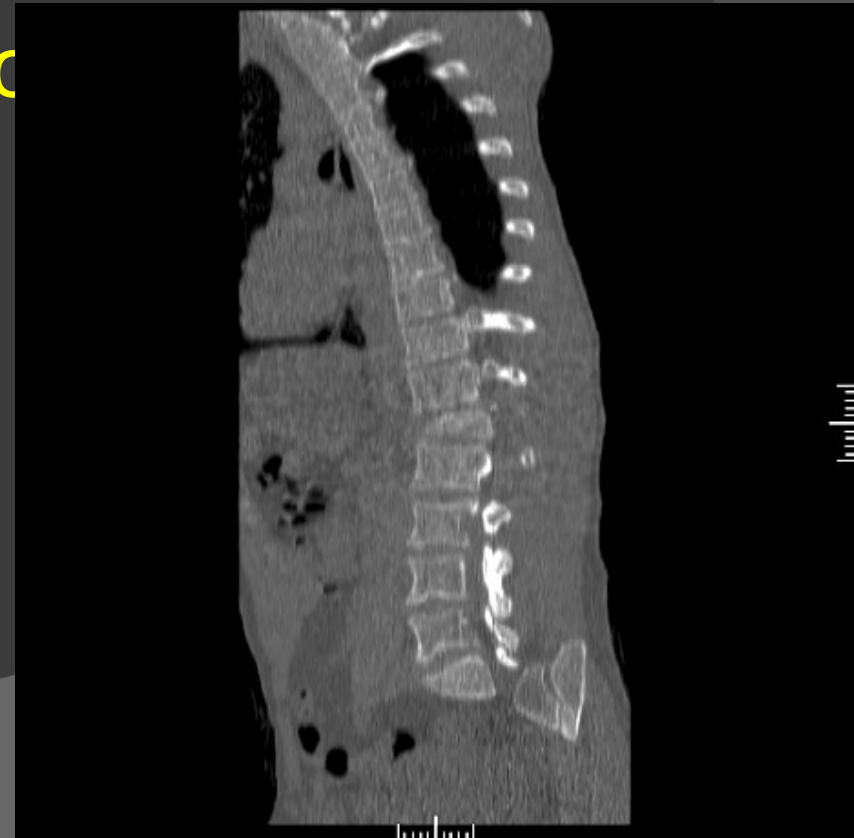Anterior and posterior injury flexion-distraction

- ⦿ Ligaments rupture posteriorly
- ⦿ Bone tissue fracture posteriorly
- ⦿ The disc rupture anteriorly

Type-C

Anterior and posterior injury with rotation

- ⦿ A+B injury with rotation injury
- ⦿ Rotation injury with oblique fracture and displacement



TYPA A KOMPRESJONS SKAÐAR

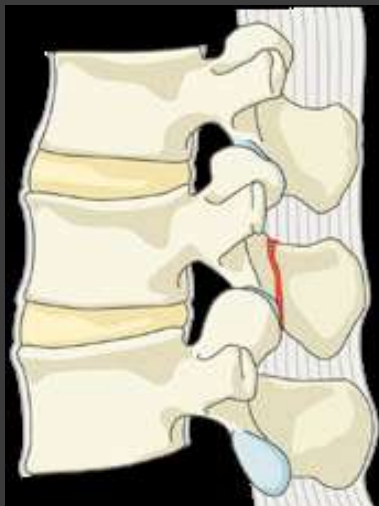


Kompresjonsáverkar

A1-A4

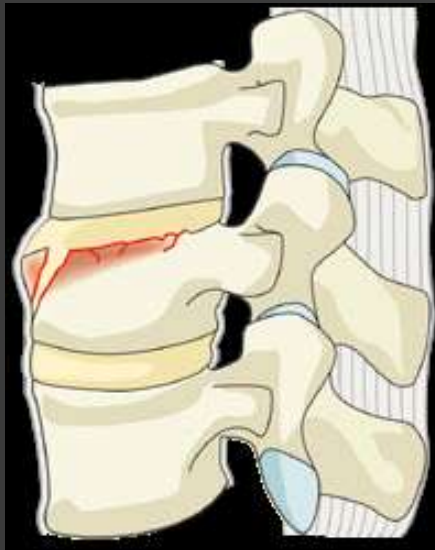A1 brot

Minor, nonstrúktural skaðar

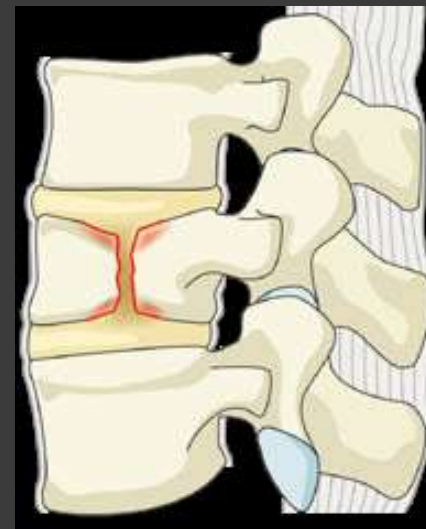


Kompresjonskaðar

A1, wedge brot

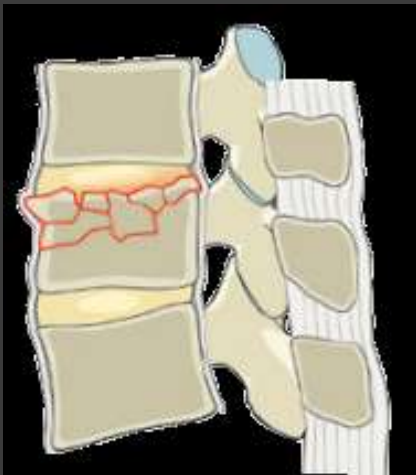

A2. Split fraktura


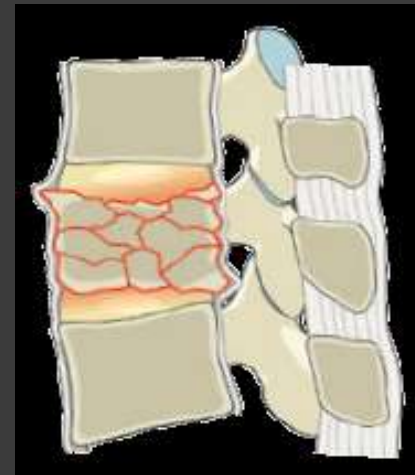


A-kompresjonsbrot

Inkomplett burst
brot



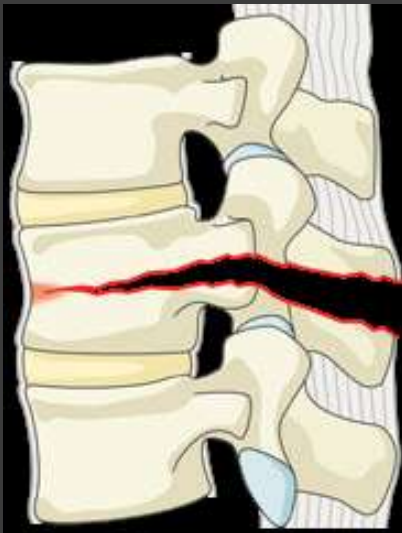Komplett burst brot



Typa B

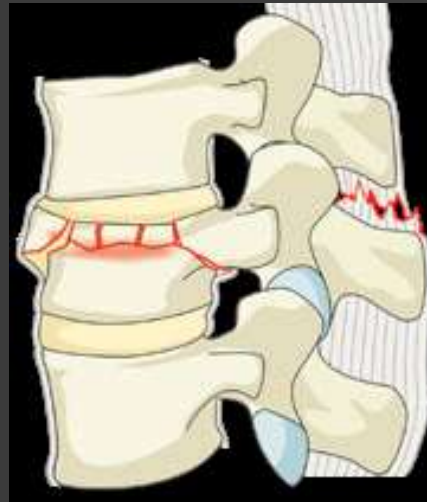Distraksjonsáverkar

Transosseoustensionsband
disruption/
Chance fraktura



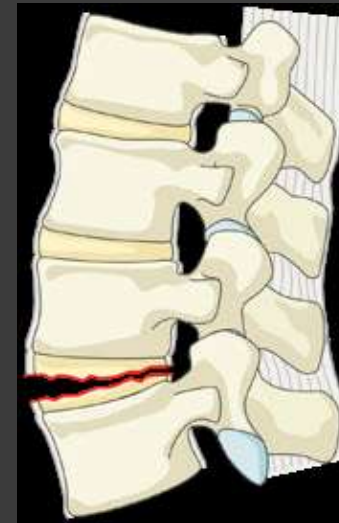B1-áverki

Posterior
tensionsband
disruption



B2-áverki


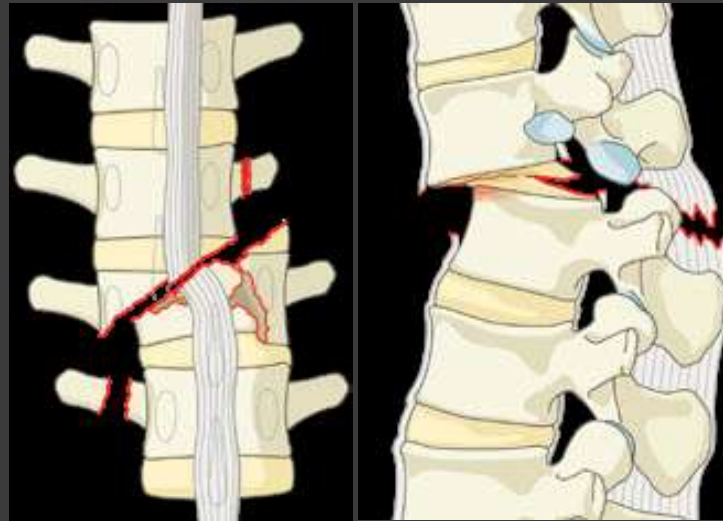
Hyperextensionsáverki



B3 áverki



Typa C Translasjonsáverkar



TLICS

TLICS 3 independent predictors				
1	Morphology immediate stability	<ul style="list-style-type: none"> - Compression - Burst - Translation/rotation - Distraction 	1 2 3 4	<ul style="list-style-type: none"> - Radiographs - CT
2	Integrity of PLC longterm stability	<ul style="list-style-type: none"> - Intact - Suspected - Injured 	0 2 3	- MRI
3	Neurological status	<ul style="list-style-type: none"> - Intact - Nerve root - Complete cord - Incomplete cord - Cauda equina 	0 2 2 3 3	- Physical examination
Predicts		<ul style="list-style-type: none"> - Need for surgery 	0 – 3 4 > 4	<ul style="list-style-type: none"> - nonsurgical - surgeon's choice - surgical




Konservativ vs kirurgísk meðferð

- ⦿ <4 punktar -> konservativ meðferð
- ⦿ >4 punktar -> kirurgisk meðferð



Take home message


- Almennur status, muna aðrir áverkar
- Tryggja stabilitet fyrir hrygginn, ef þörf er
- Trauma CT
- Dokumentera, skriflega. Second survey eftir þörfum
- Legga meðferðarplan í samráði við vakthafandi bæklunarlækni ef thoracolumbar áverkar og við taugaskurðlækna ef hálsáverkar með taugaeinkenni



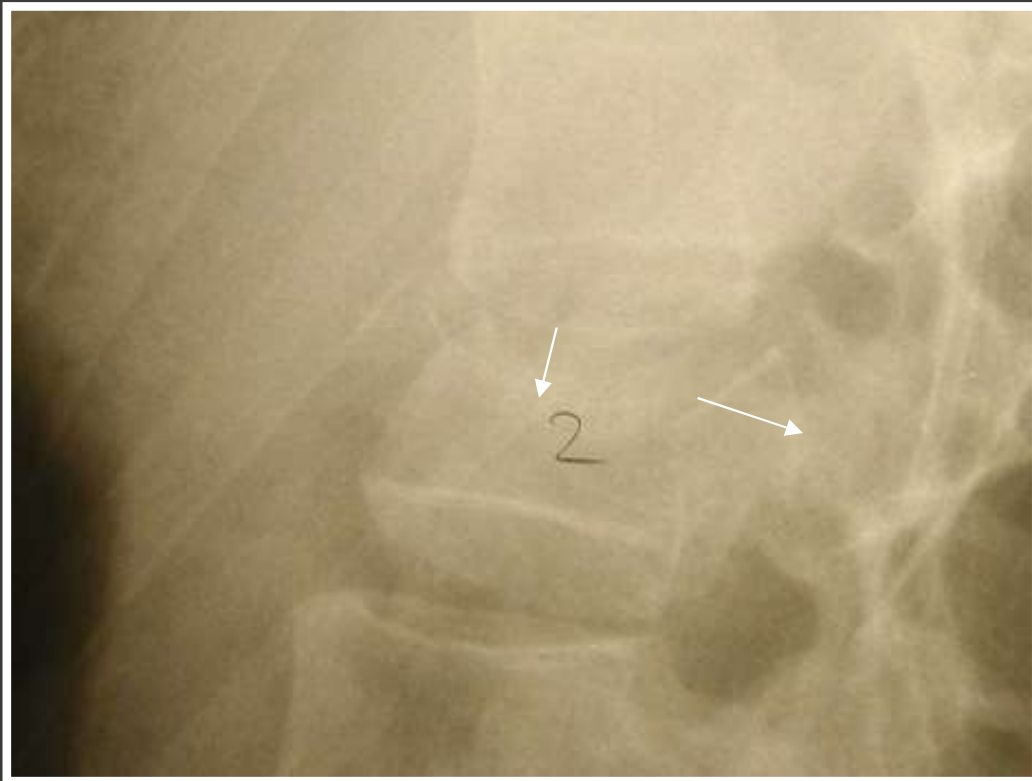Klinisk eksempel på ryggbrudd og operativ behandling



Bilvold-ikke i sikkerhetsbelte



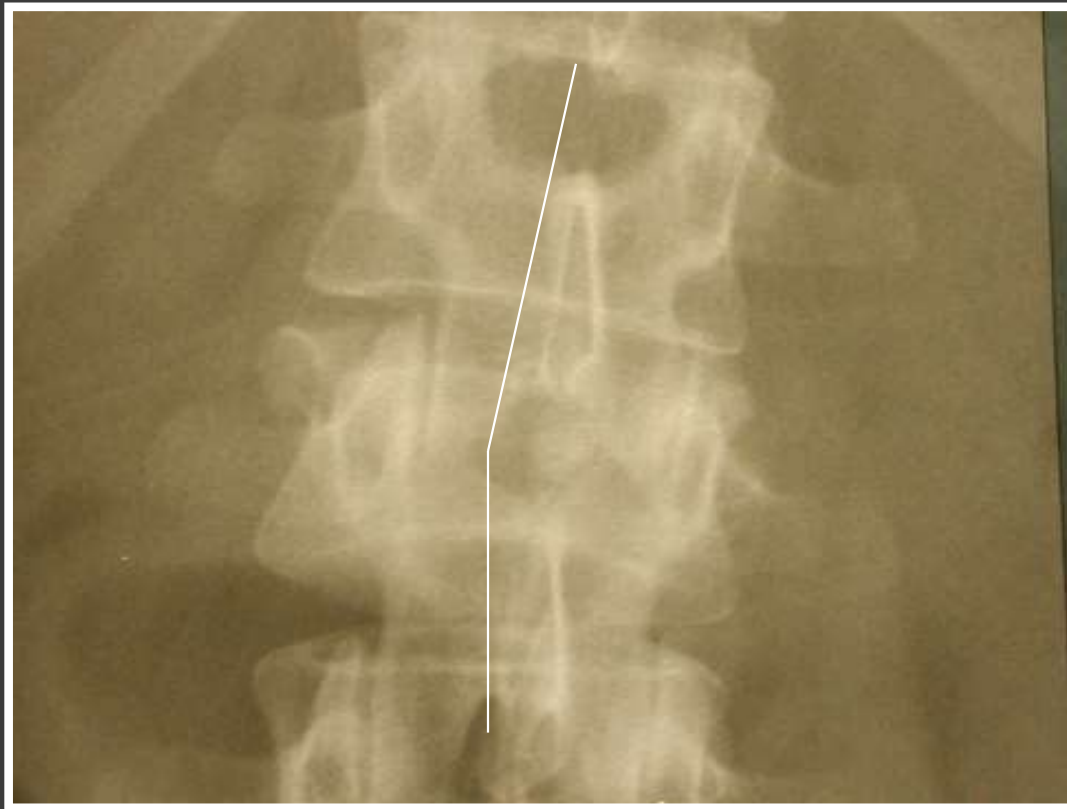
Burst fracture L₂



Retropulsion of the posterior bone fragment



L₂ Burst fractur

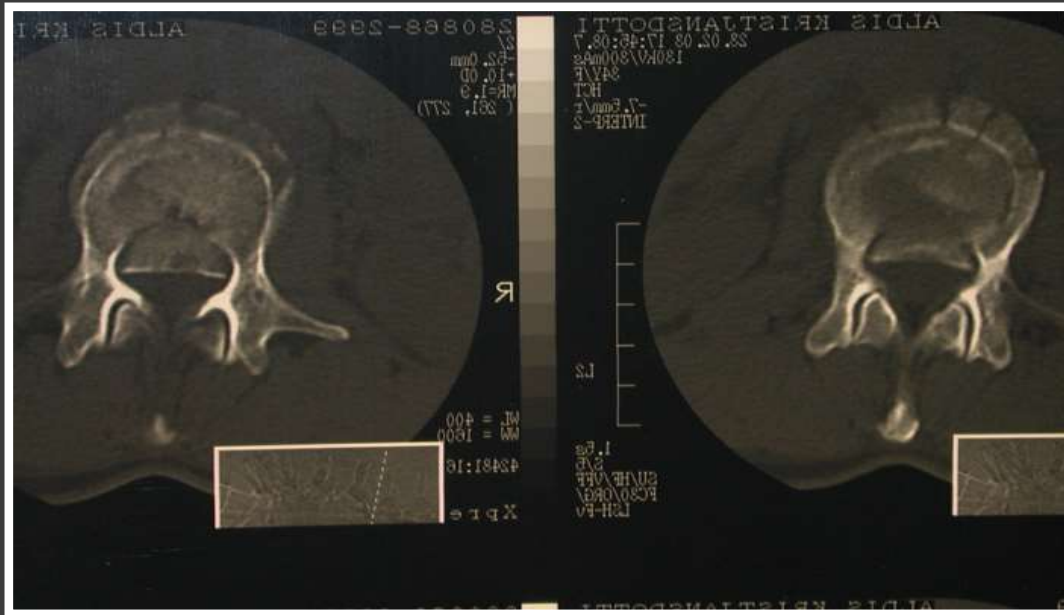


Høger convex scolios



L₂ Burst Fracture

CT-axial




Bakvegg brudd

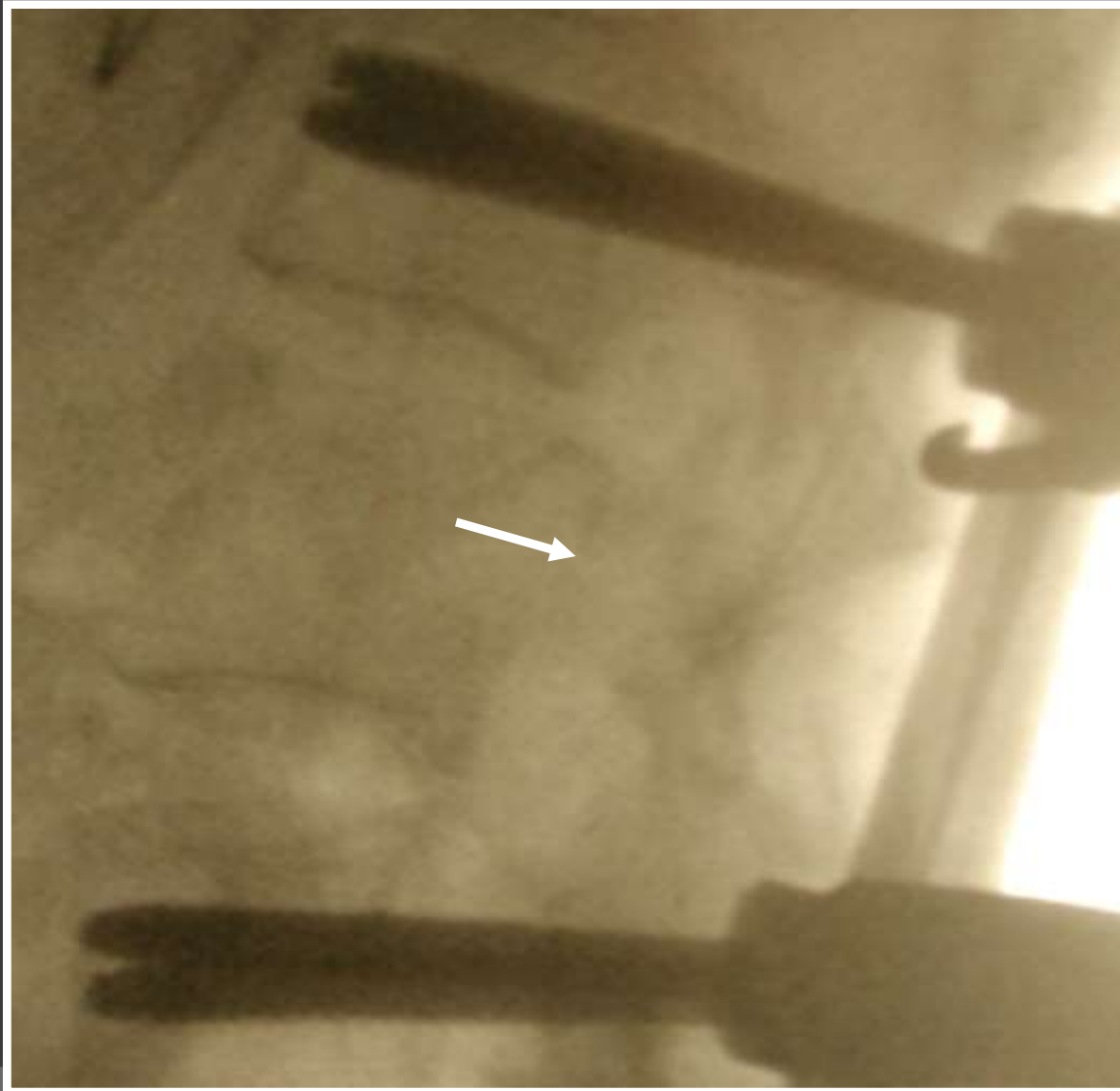
Økt avstand mellom pedikler

Spinal kanal trengsel
50%

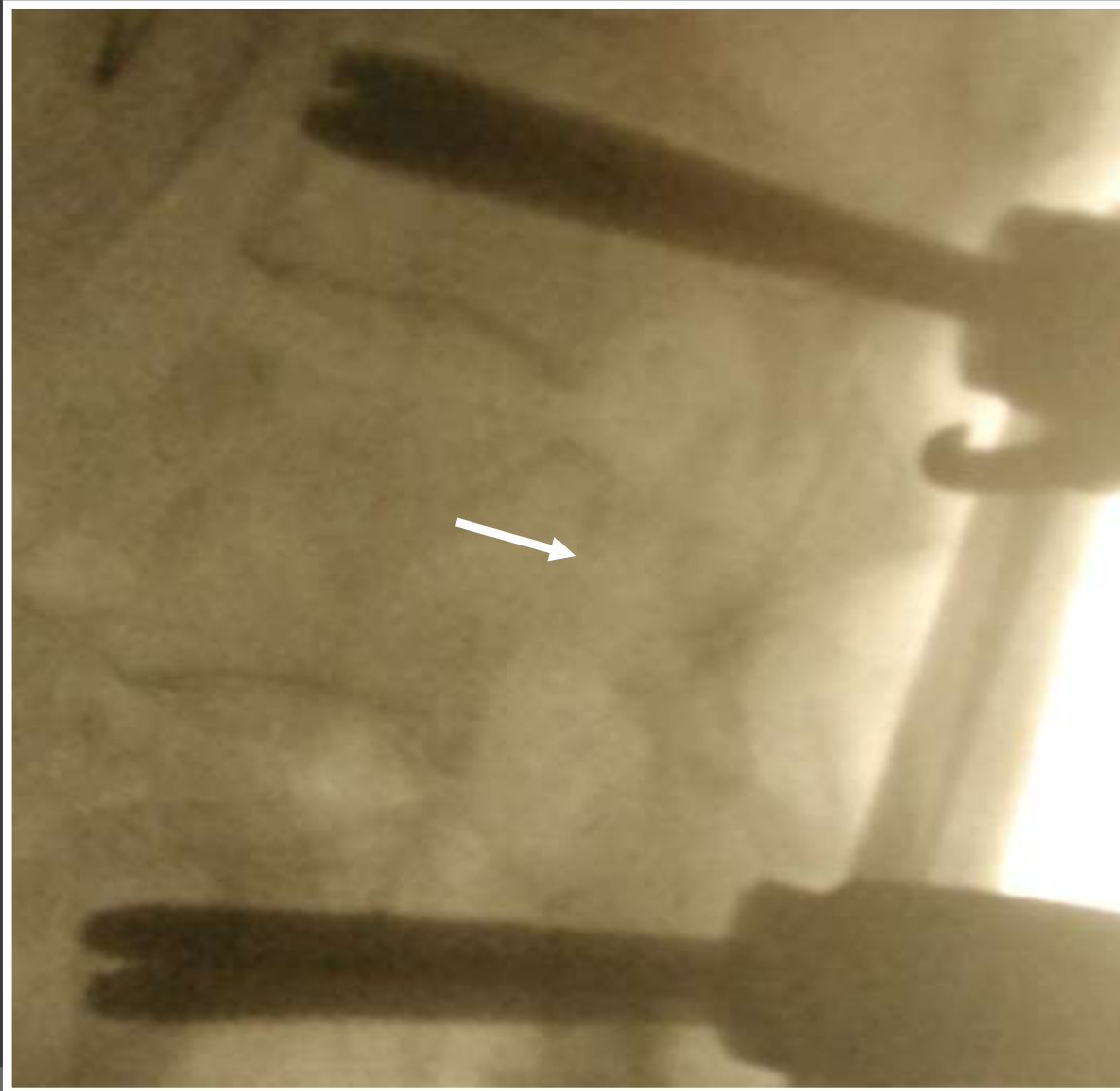
Incomplete burst fracture



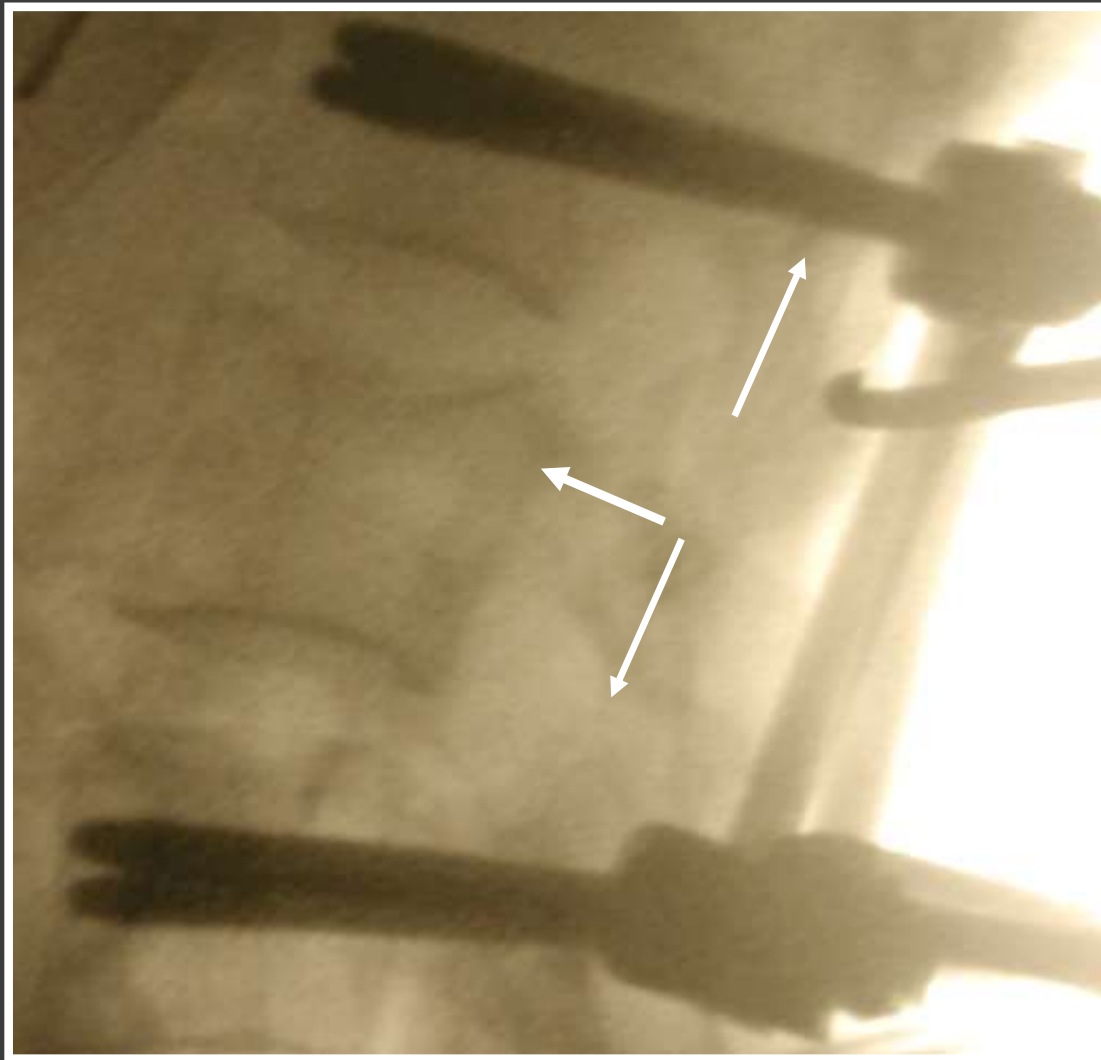
L₂ Burst fracture



L₂ Burst fracture



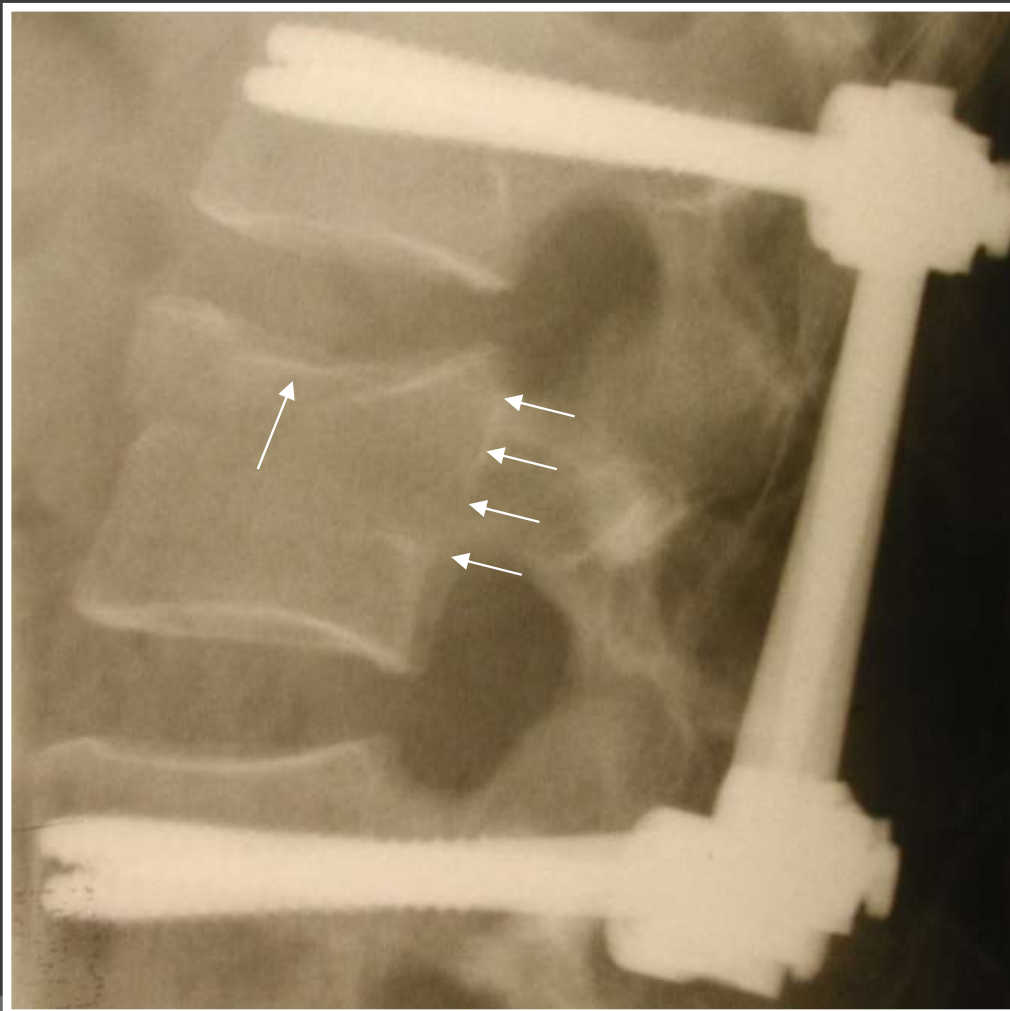
L₂ Burst fracture



Indirect anterior decompression
of
the neurovascular elements
through posterior reduction
by distraction



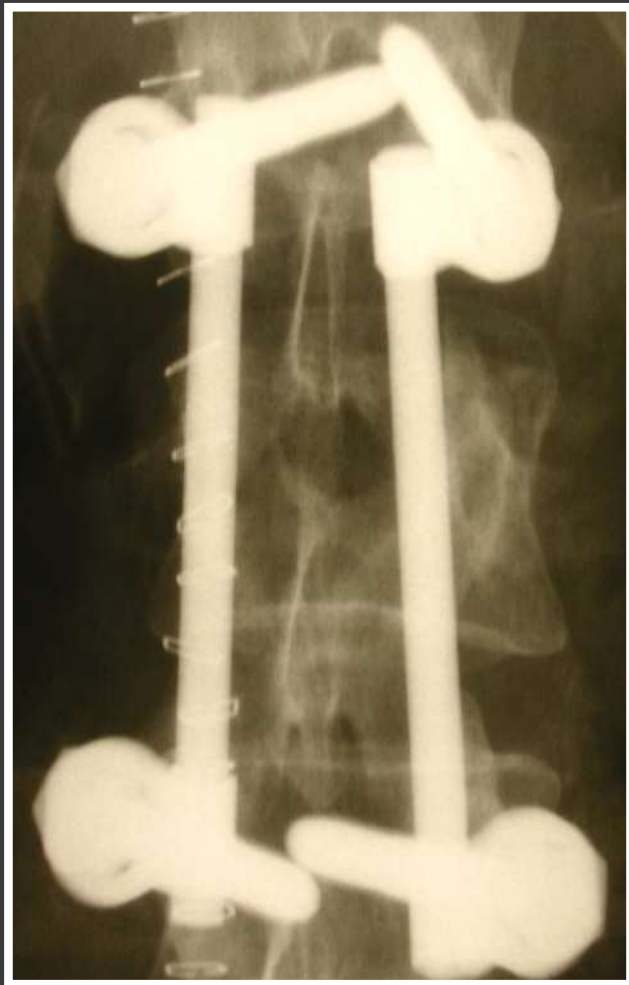L₂ Burst Fracture



Reponeraď
bakre fragment



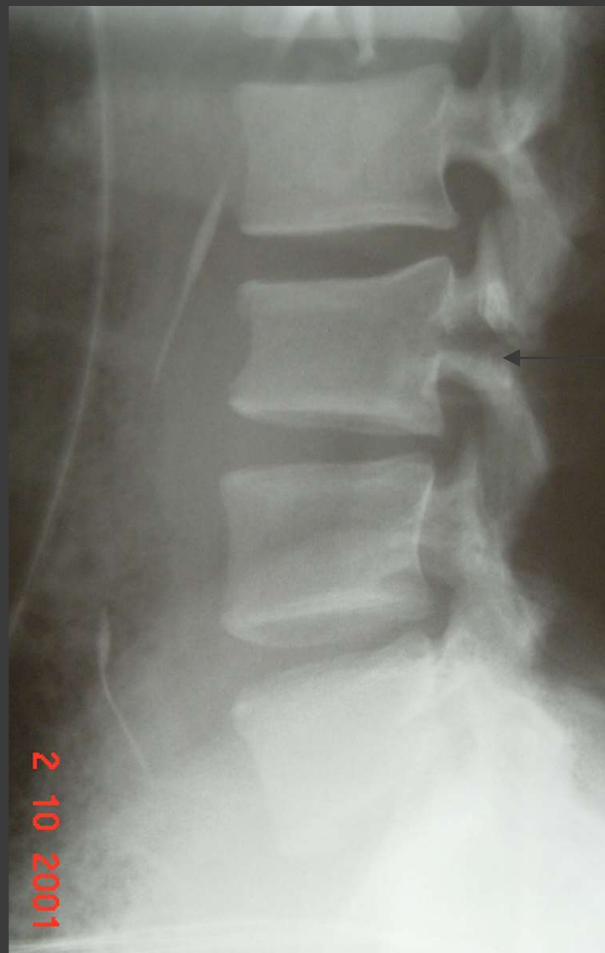L₂ Burst Fracture



Scolios reponert



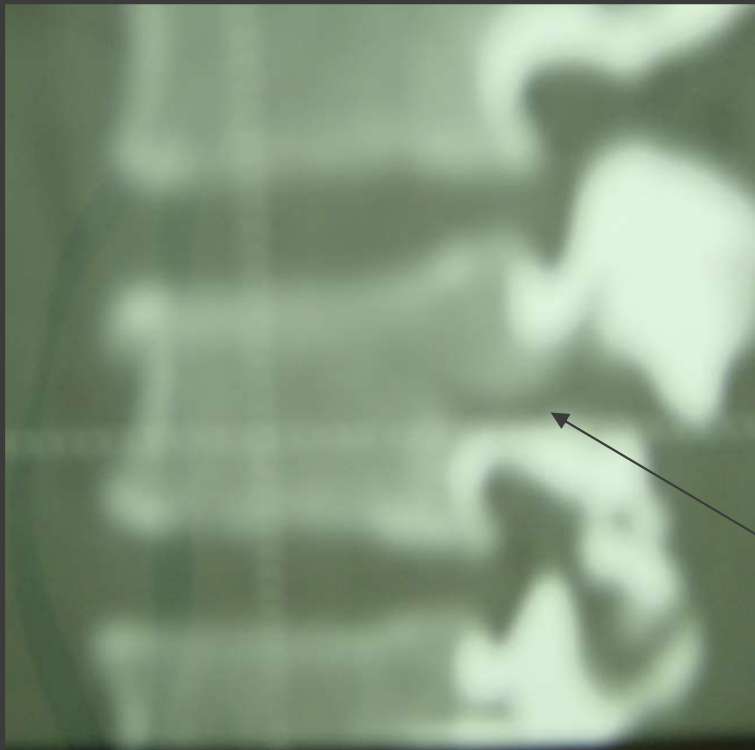
Chance fraktur – L3



Brudd og glidning



Chance fraktur



L-3 brudd

Brudd igjenom korpus

Brudd igjenom pedikulus

Brot igjenom beinbue

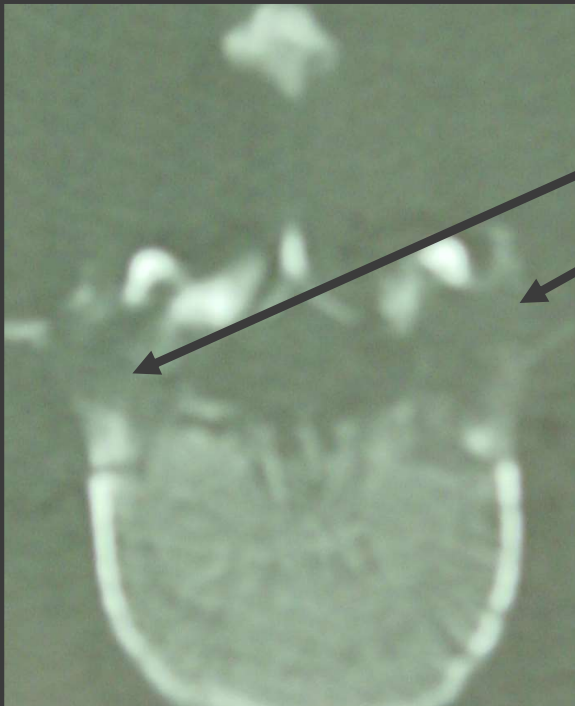
Brot igjenom pr spinosi

Total ruptur/brudd igjenom alla 3 kol



Chance fraktur axial-CT

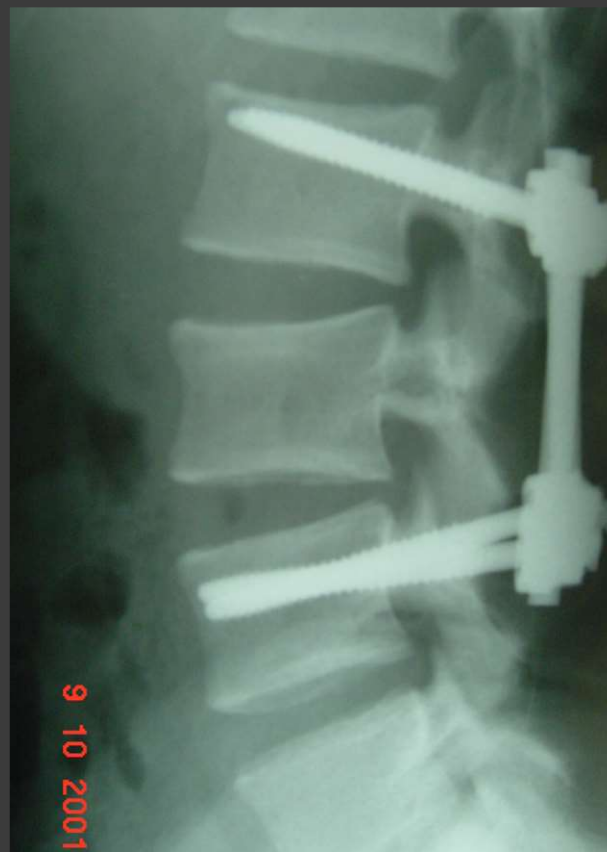
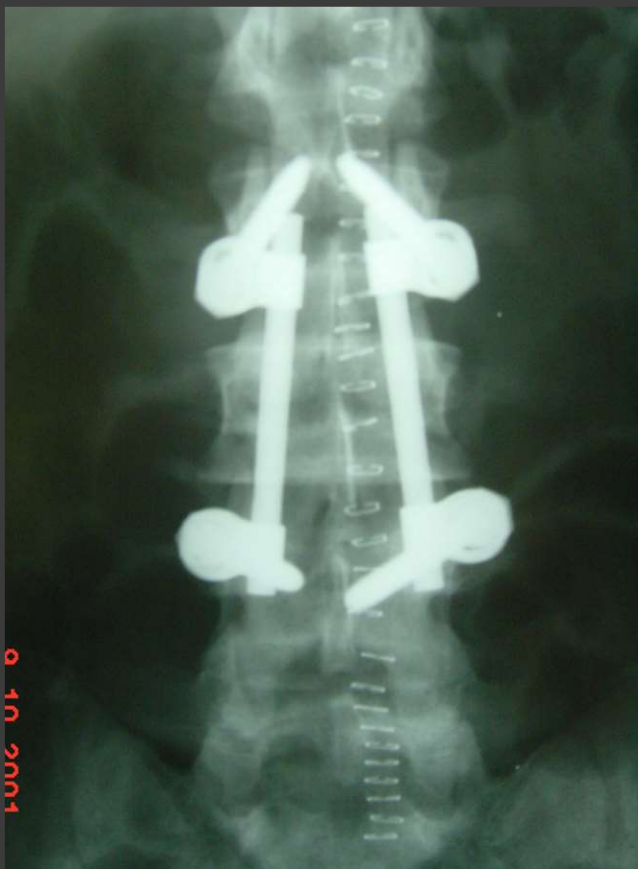Brudd ipedikler



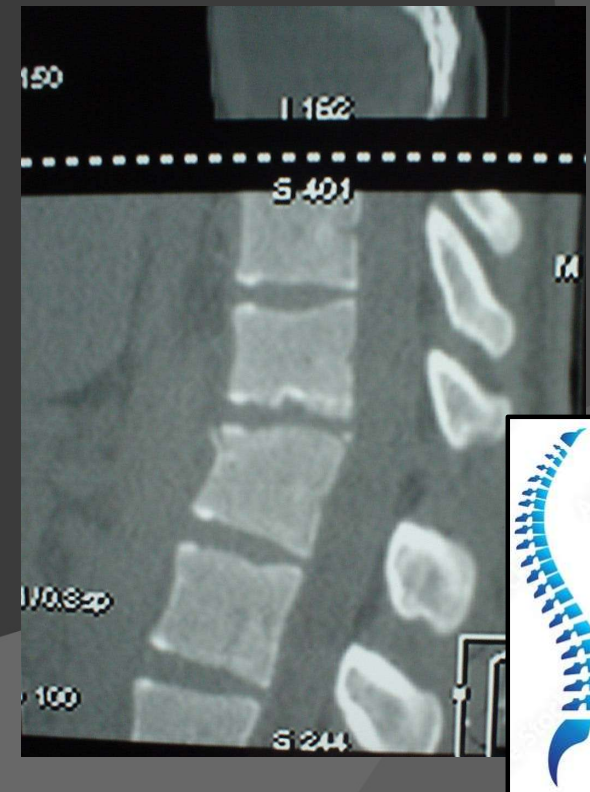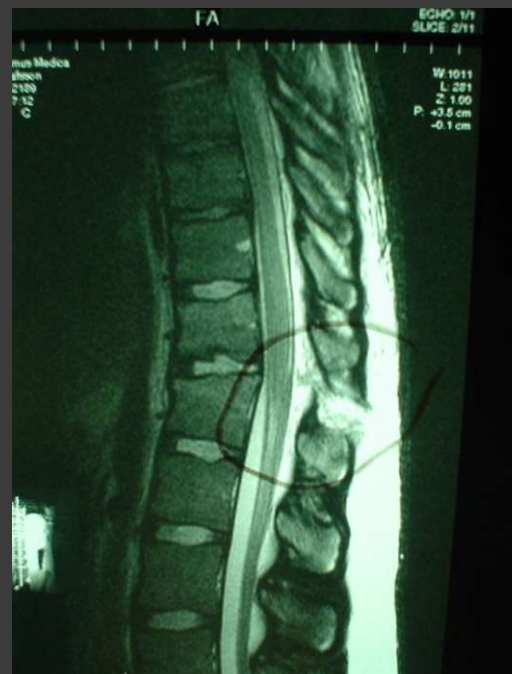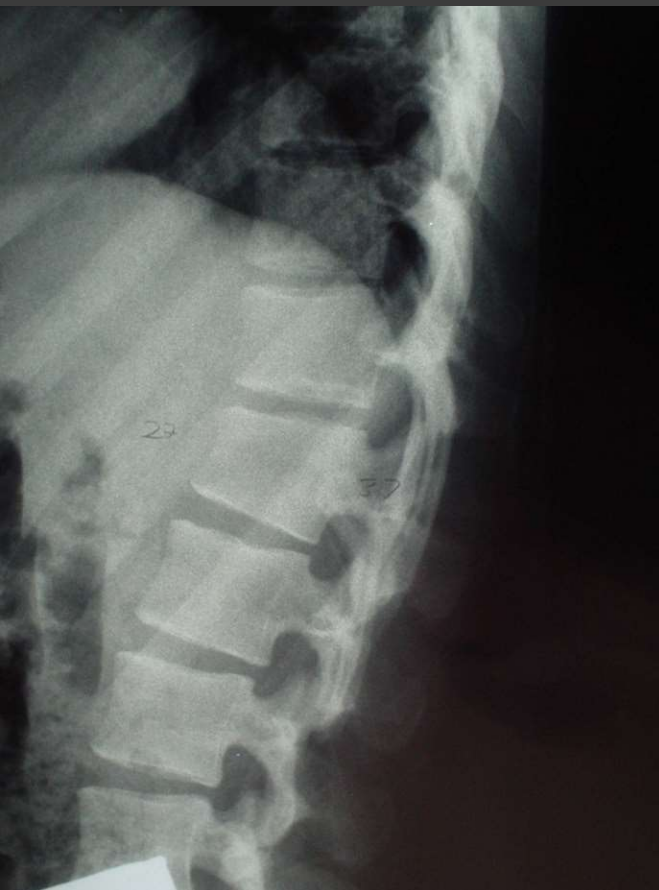L-3



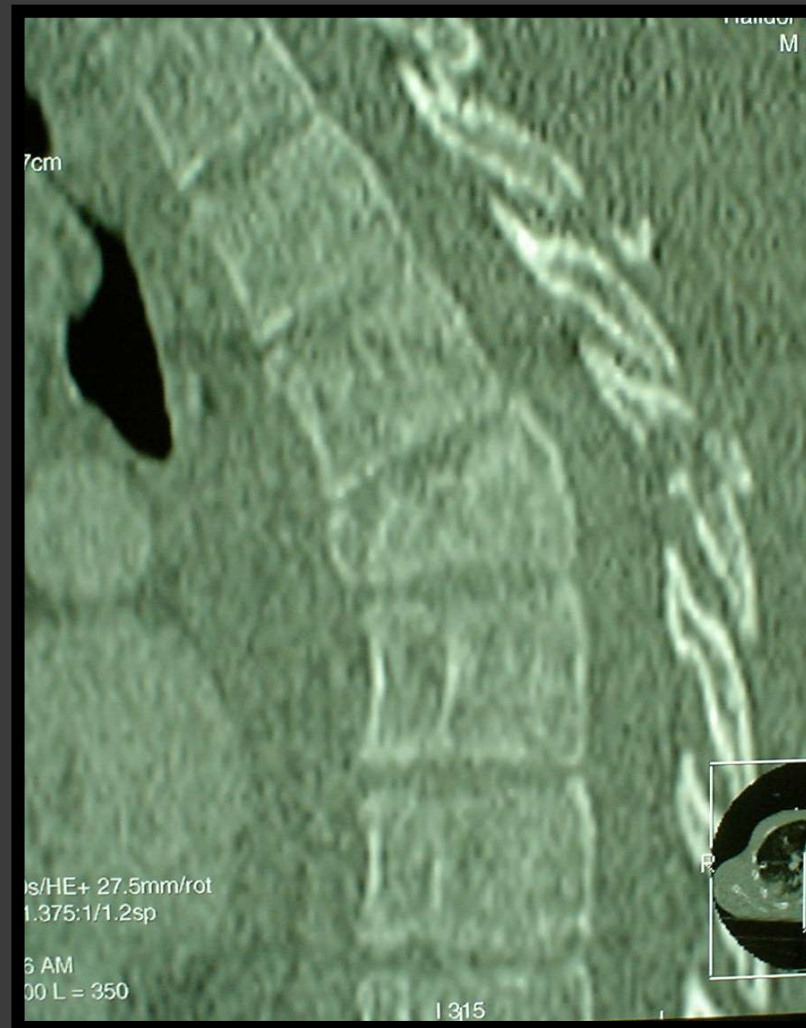Chance fraktura - op



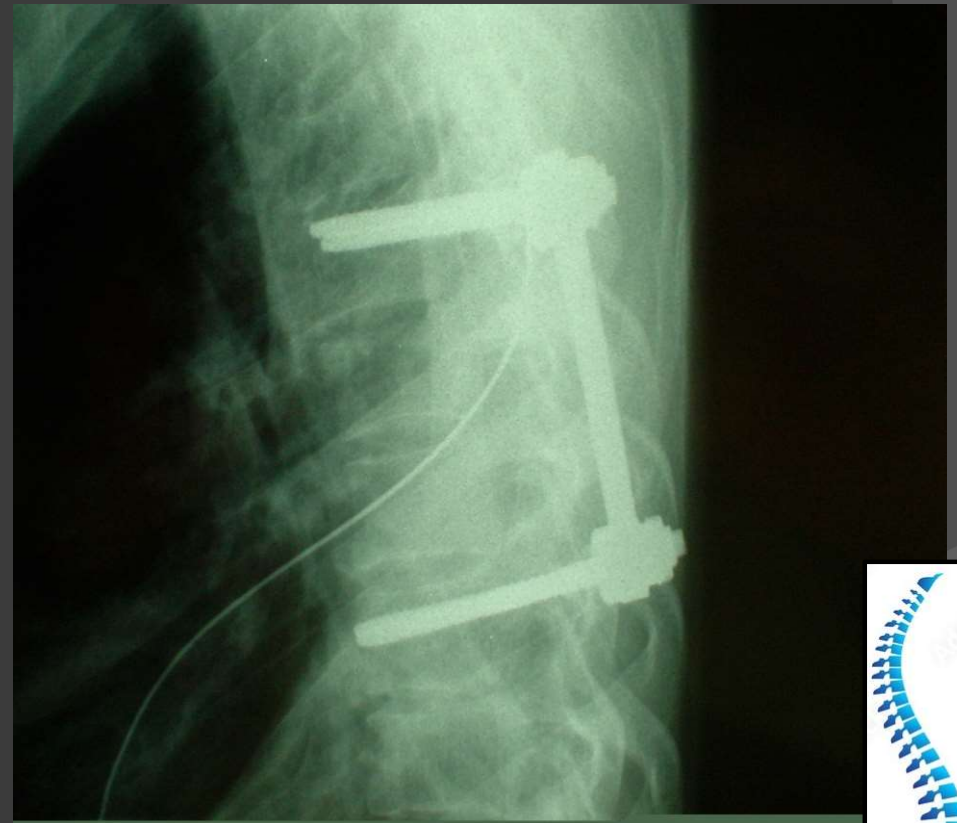
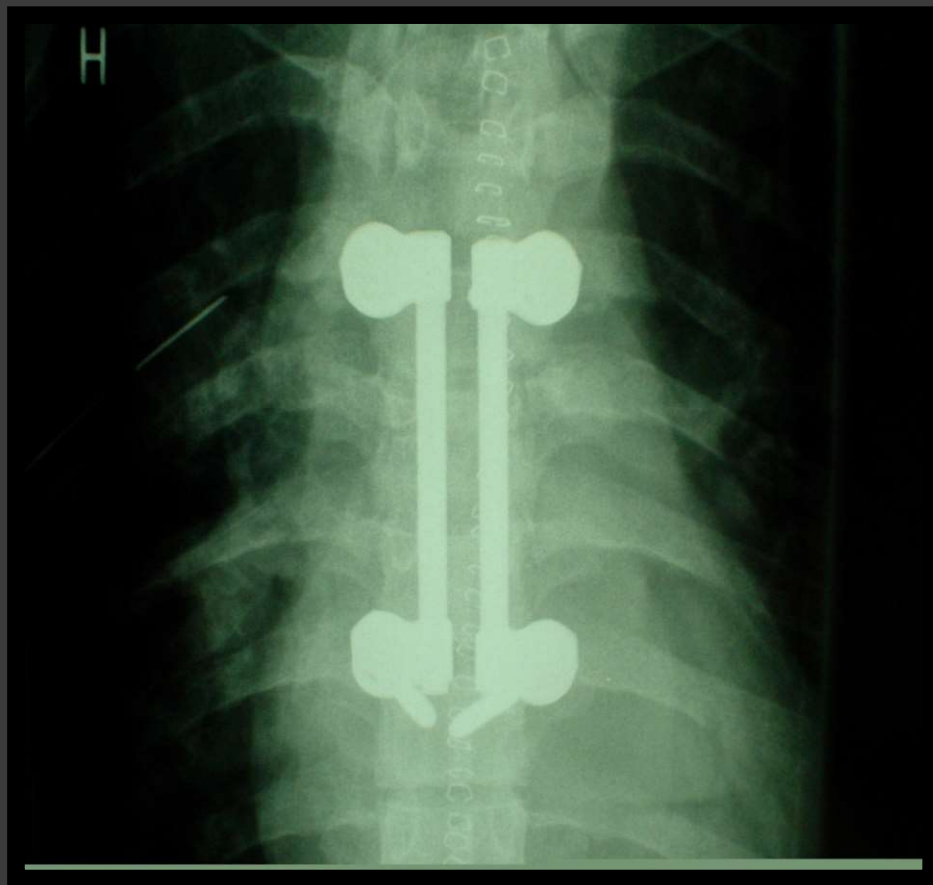
Flexion-Distrraction injury



2-D reconstruction Th6



Flection distraction injury



Transport av ryggskadede pasienter

1. Vakuummadrass
2. Flygambulans-helikopter



Helikopterambulans Takk

