



Ortopedia– börn

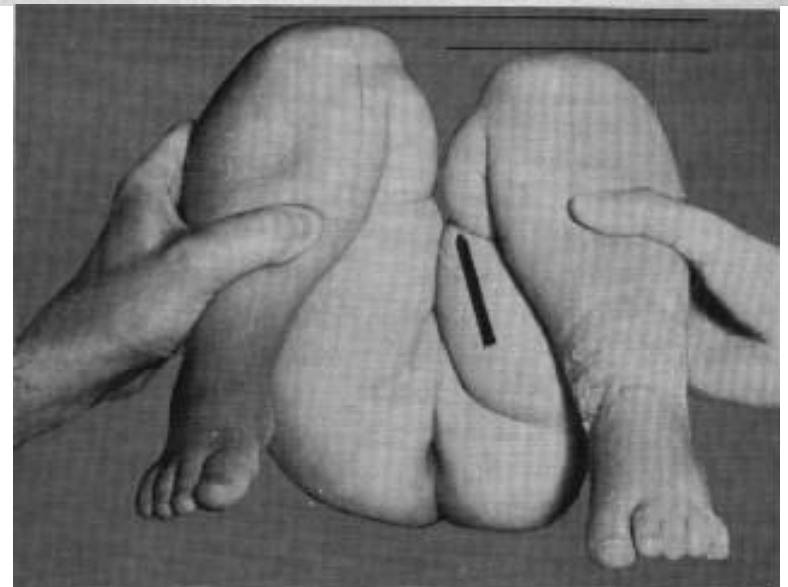
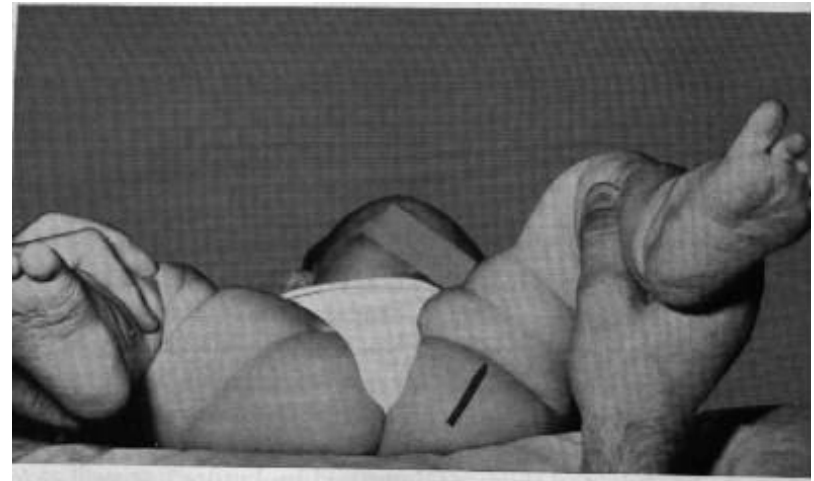
**- Sjúkdómafræði –
Barnasjúkdómar (köld ortopedia)
Barnaáverkar (heit ortopedia)**

Halldór Jónsson jr

Bæklunarskurðeild LSH og Læknadeild HÍ

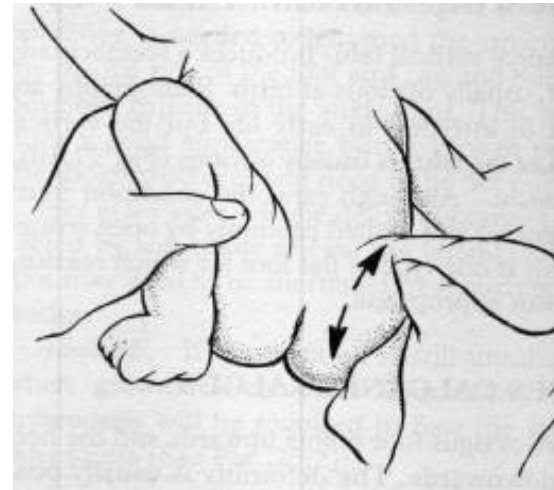
Meðfætt

- Luxatio coxae congenita -
(Meðfætt liðhlaup í mjöðm)
- ATH: viðbótarfellingar á læri og lægra hné!



Meðfætt

- Einnig kallað: CDH (Congenital Dislocation of Hip)
 - Ortholani próf
 - Ómskoðun: sér liðkúlu (bara brjósk)



- Síðar rtg: ath Shentons lína

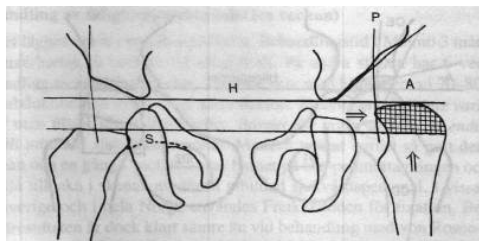
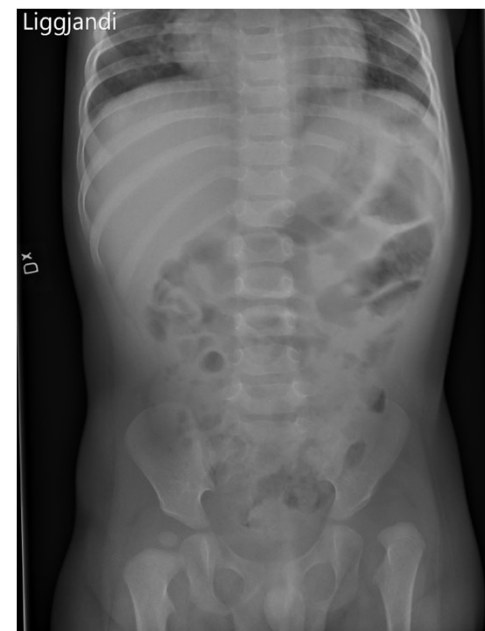
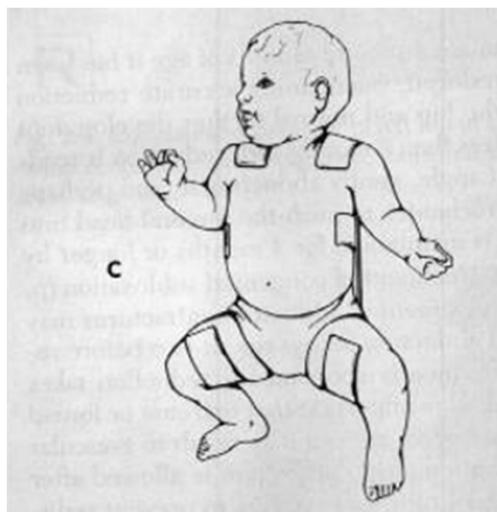
Fig. 6.2 Röntgenologisk diagnostik av kongenital höftledsluxation redan i födselperioden och innan caputkärnan förkalkats med användande av Hilgenlinjen. Observera att röntgenologen måste vara förtrogen med luxationsmanövrerna för att hålla höftleden i luxerat läge vid röntgenundersökningen. H = Hilgenlinjen, P = Perkins linje, A = Acetabularvinkel, S = Shentons linje.

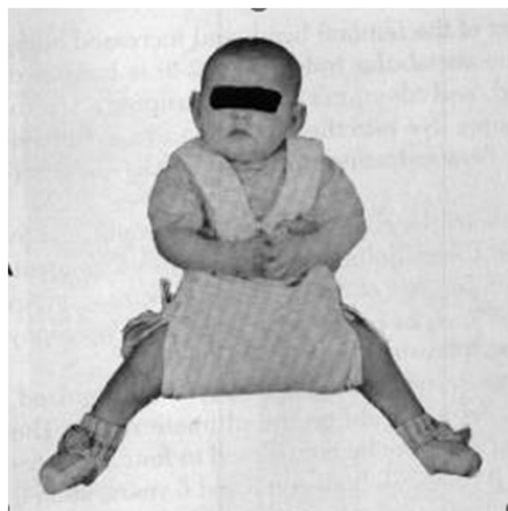


Meðfætt

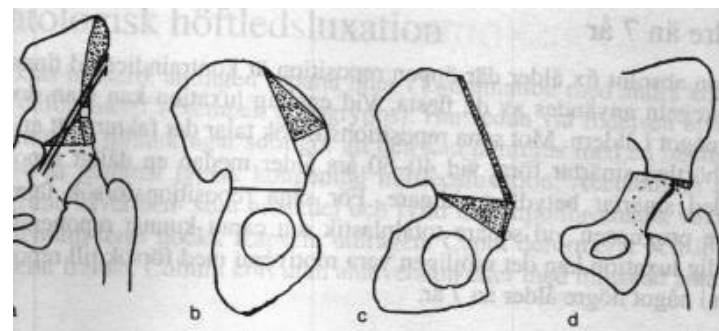
- Von Rosen skinna
- - fyrstu 6-8 v



- Frejka buxur
- -næstu 6-8v

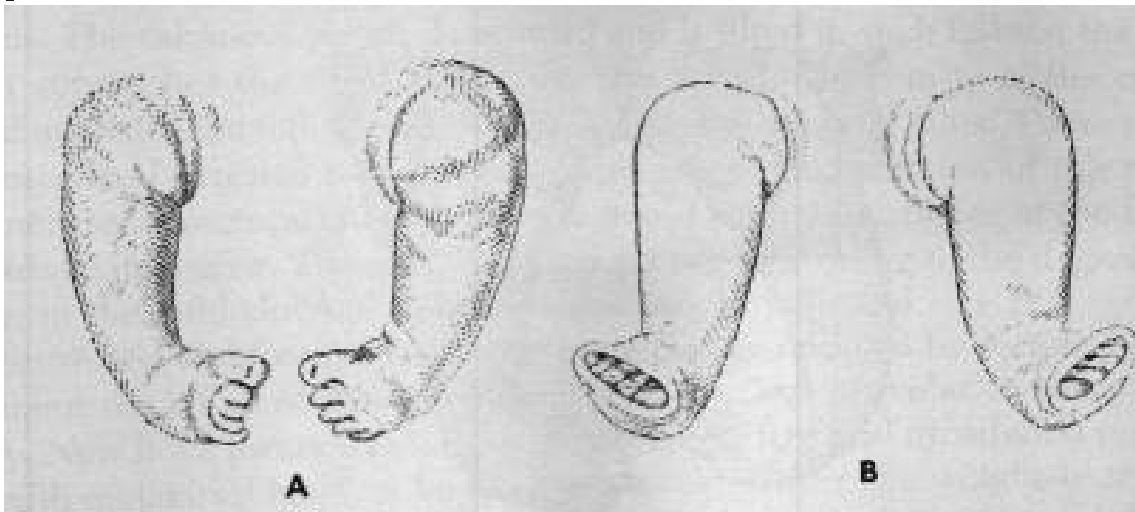


Ef ekki gengur með spelkur!

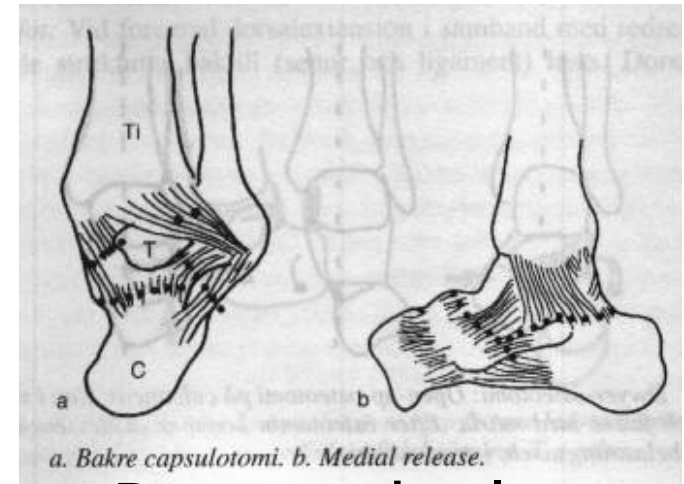


- Salter osteotomia (a,b,c)
- Chiari osteotomia (d)

Meðfætt

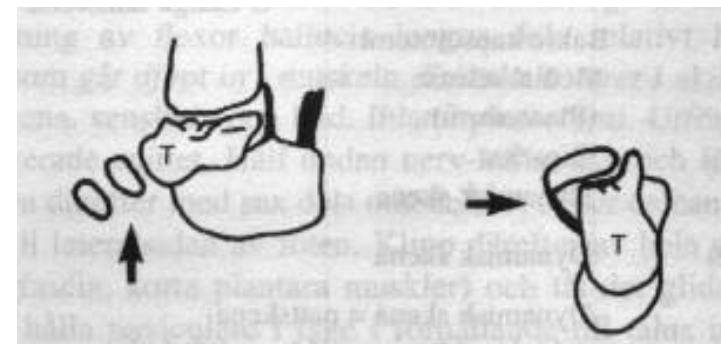


- Pes equinovarus adductus (klumbufætur)
 - Fyrir og eftir "redressing"



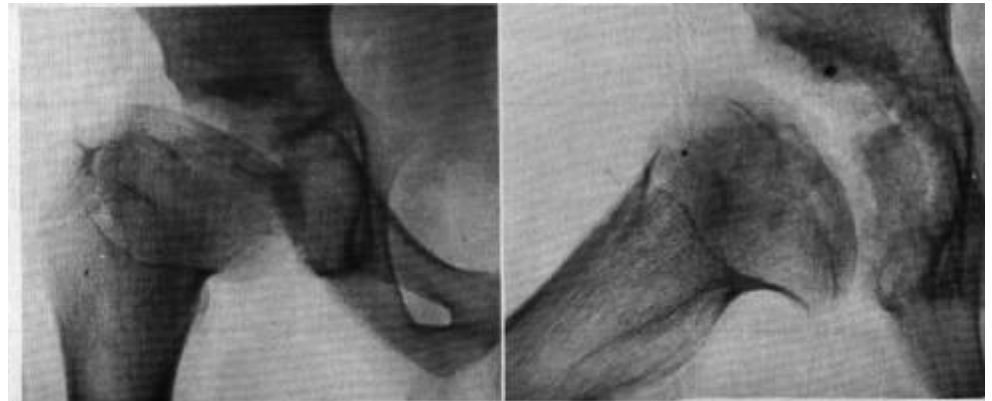
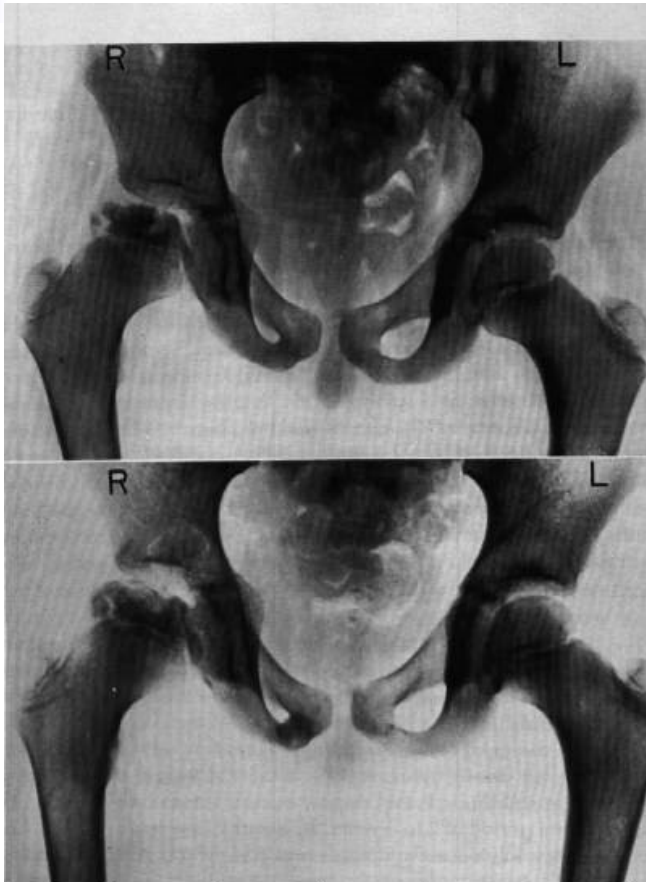
a. Bakre capsulotomi. b. Medial release.

Post-med release



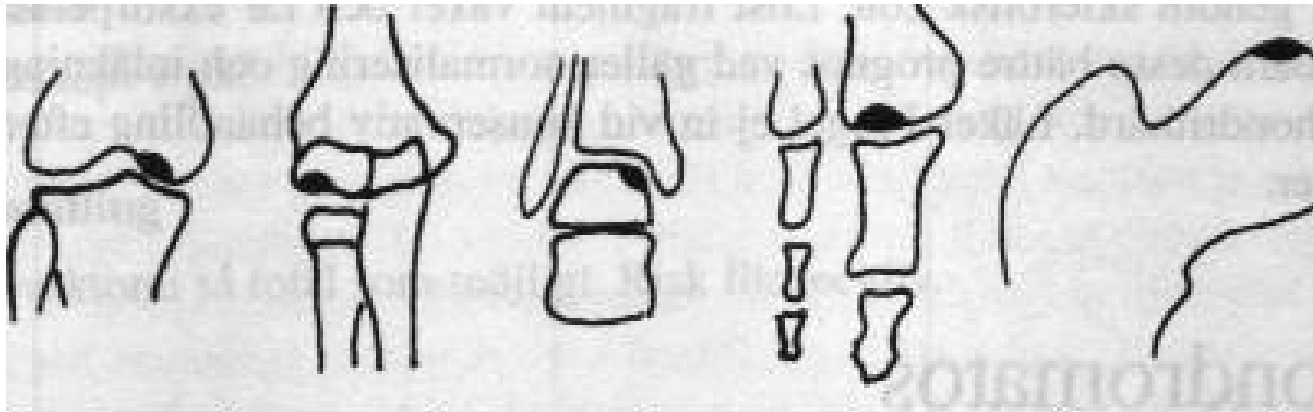
Talus necrosis

Blóðrásartruflun



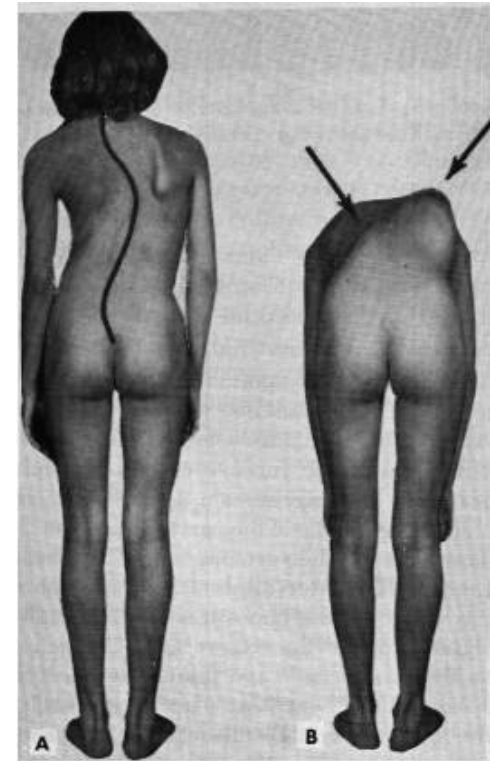
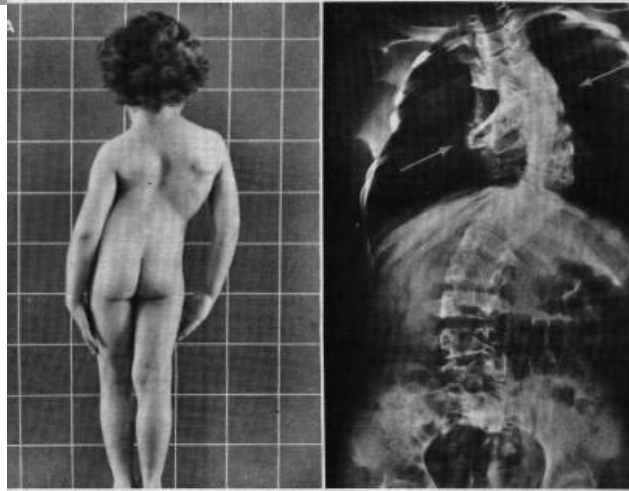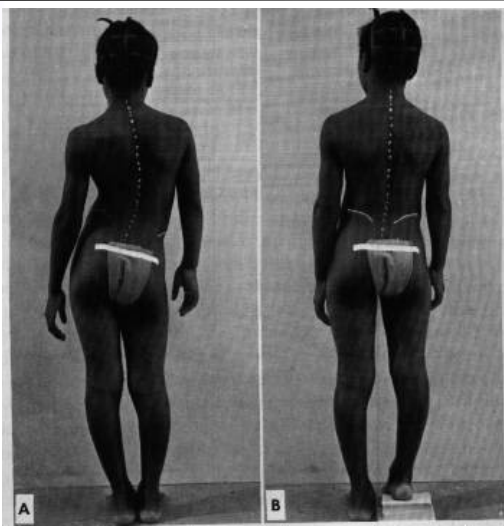
- Coxa magna
- Perthes –
 - “caput necrosis” í mjöðm

Blóðrásartruflun



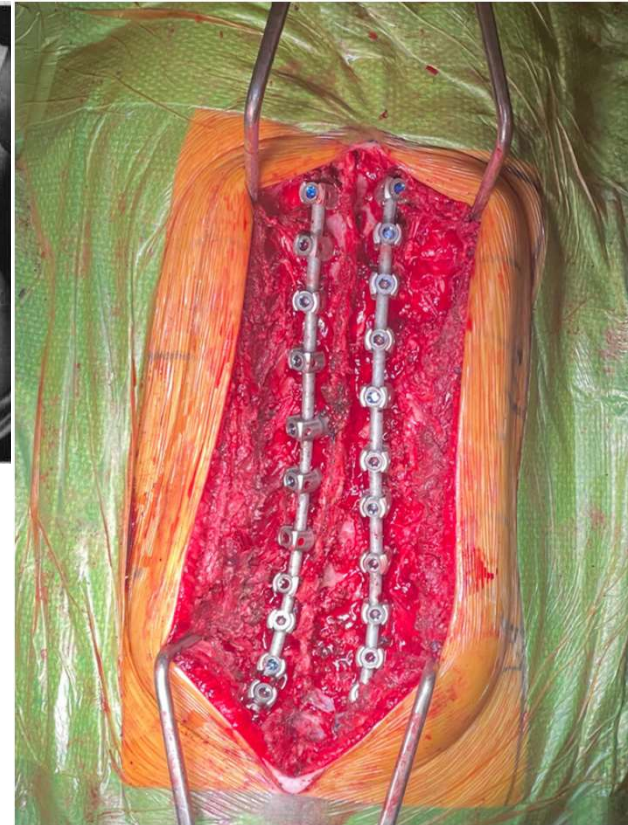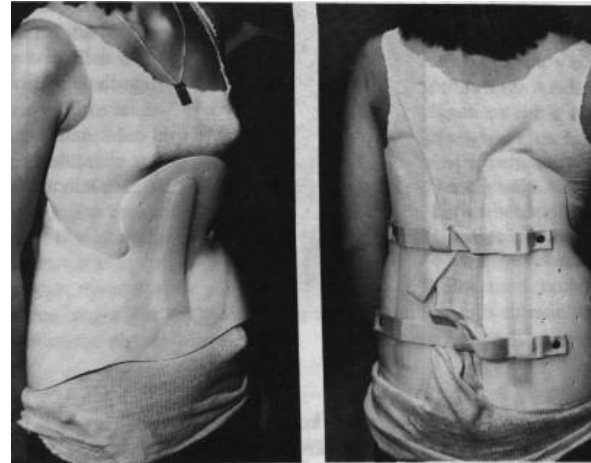
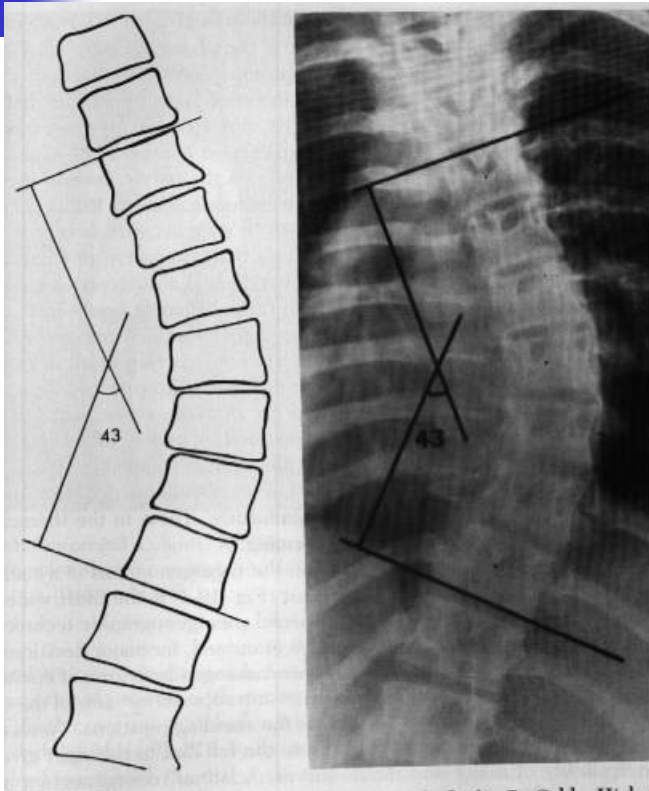
- "Osteochondritis"
 - getur orðið "dissecans" (laus biti)

Vaxtarafloegun - truflun



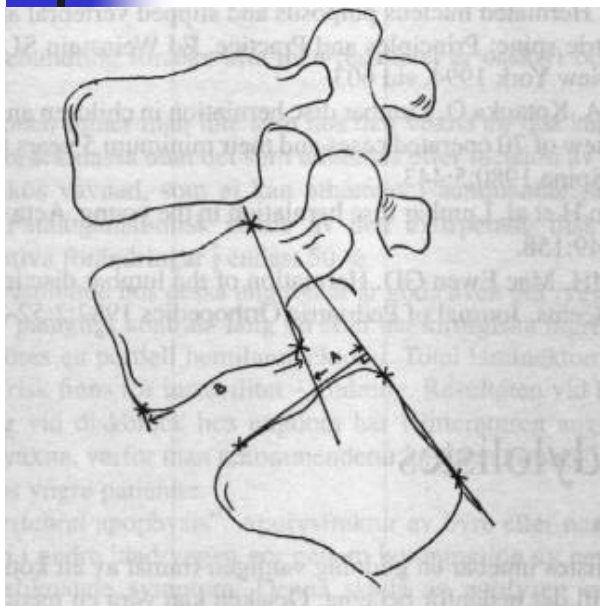
- Scoliosis – hryggskekkja
 - Functional
 - Congenital
 - Idiopathic (algengast – „fermingarstelpa“)

Vaxtar aflögun - truflun

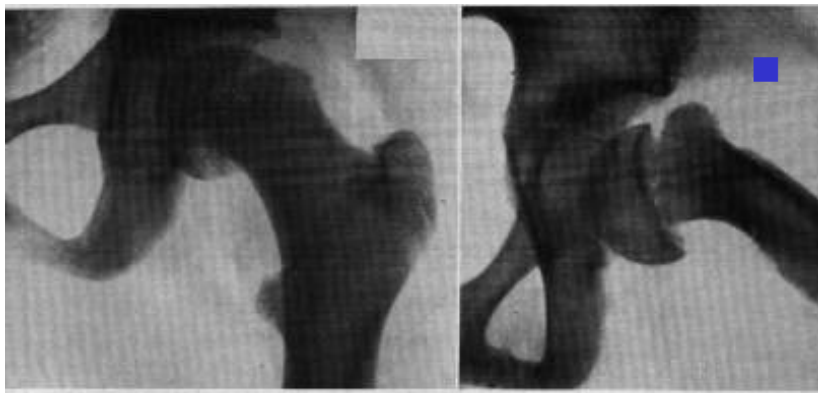


- Scoliosis – hryggskekkja
 - Cobbs horn
 - Boston belti
 - Aftari upprétting og spening

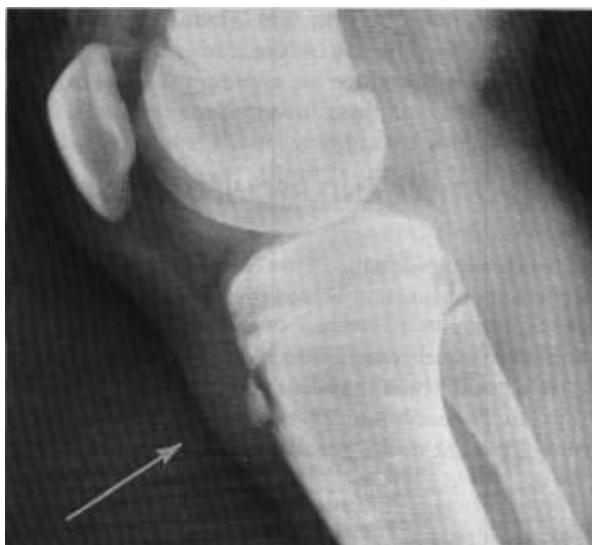Vaxtarafloegun - álag



- Spondylolysis
 - hryggskrið

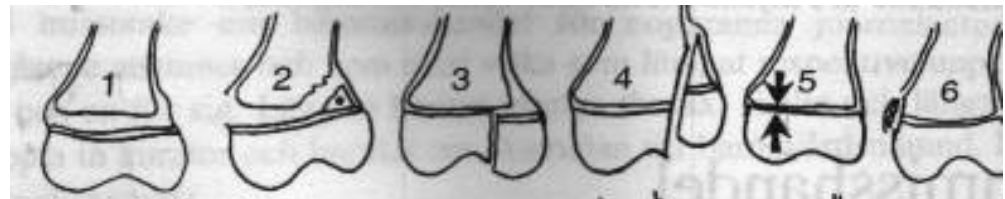


- Epifysiolysis
 - vaxtarlínuskrið

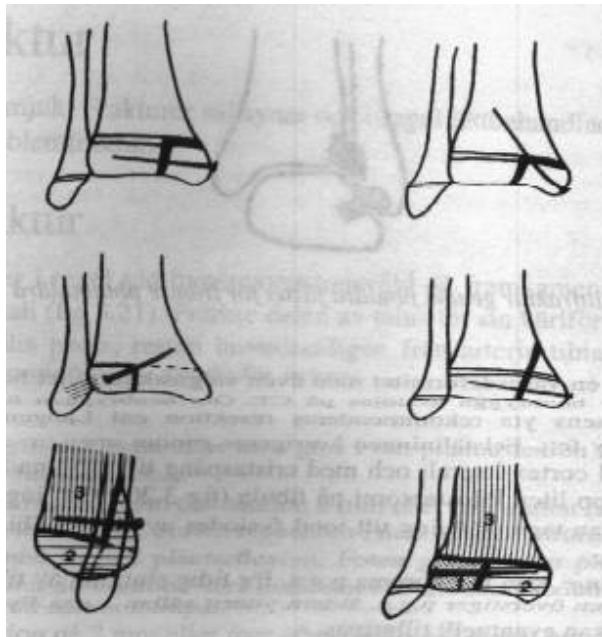


- Osgood-Schlatter
 - Slatter sjúkdómur

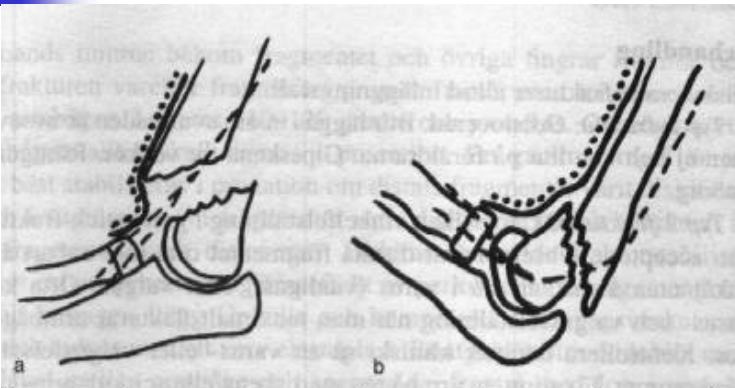
Áverkar - brot



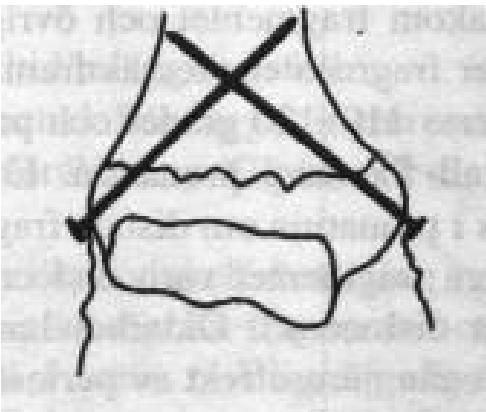
- Vaxatalínuáverkar: Salter-Harris



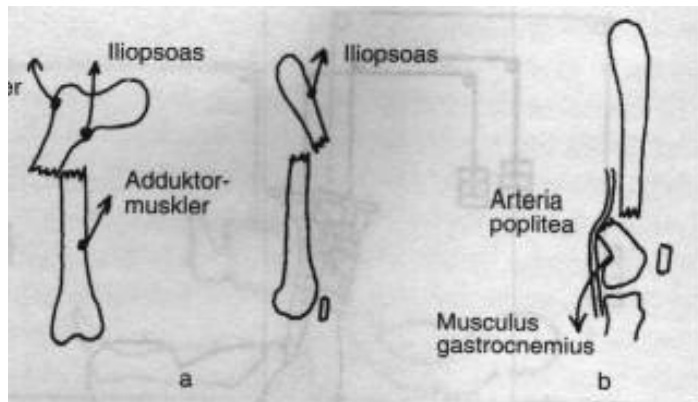
Áverkar - brot



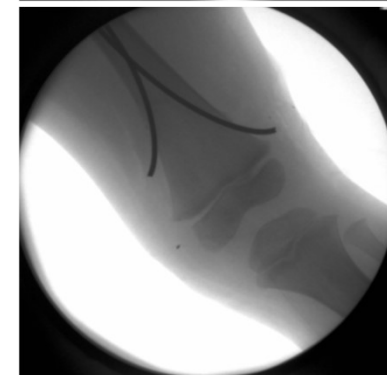
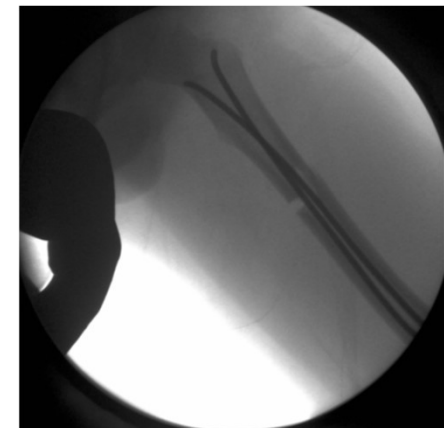
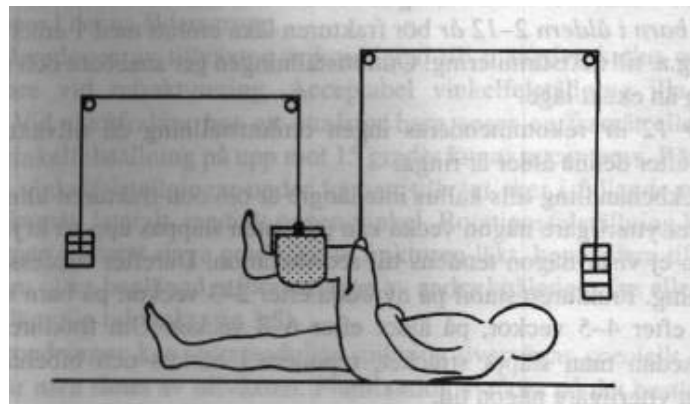
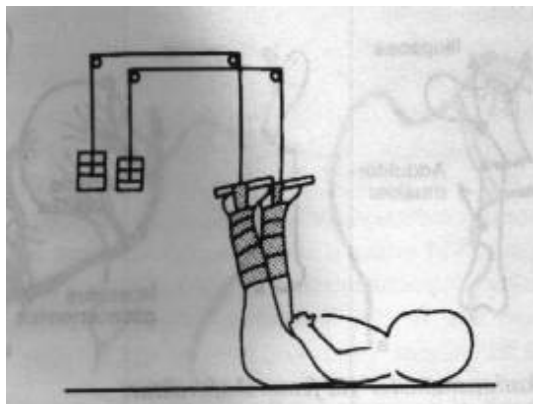
- Supracondylar humerus brot
 - ATH púls - compartment
 - Lokað/ opið rétt og pinnað



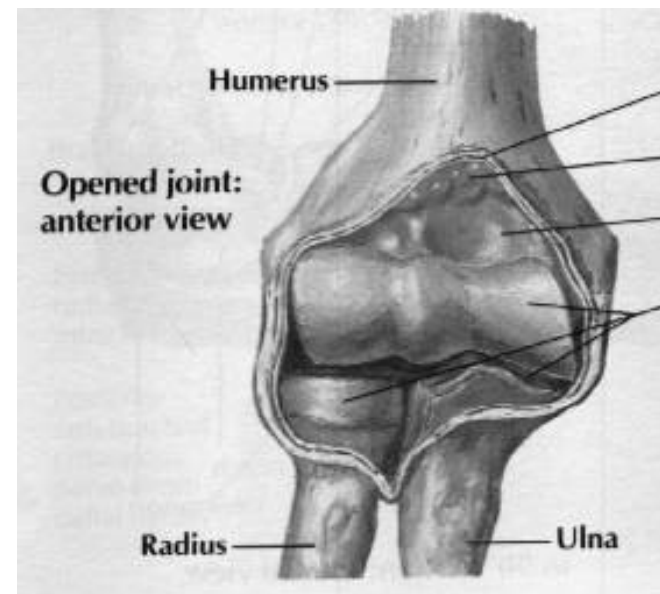
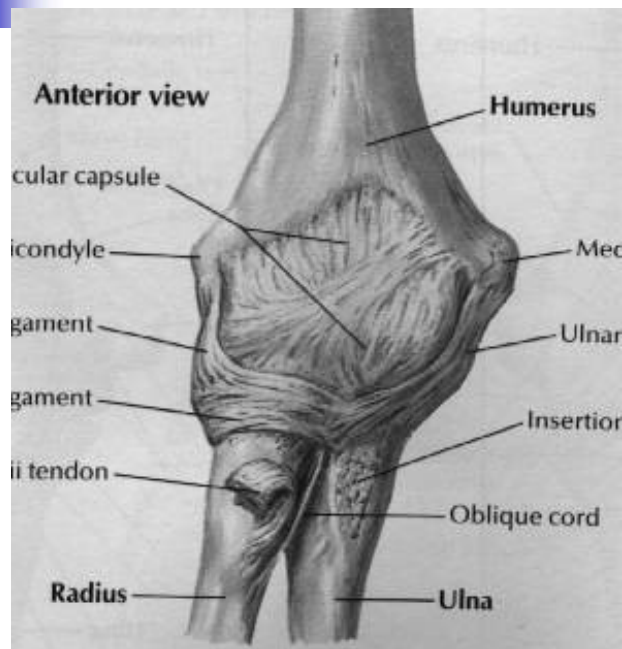
Áverkar - brot



- Skaftbrot
 - Strekkur (Gallow og 90-90)
 - Mergnagli (TEN)



Áverkar - liðhlaup



- Olnbogi
 - “Pig / nursemaids” liðhlaup