



# Ortopedia– börn

---

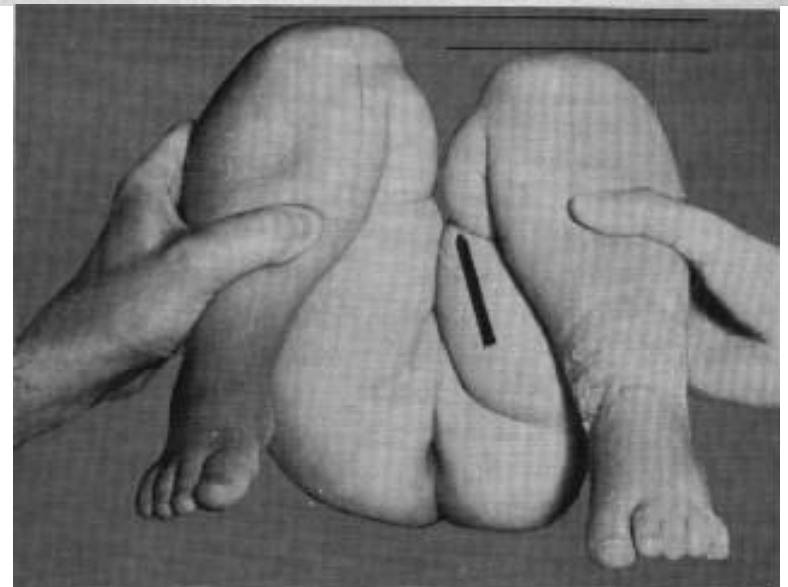
**- Sjúkdómafræði –  
Barnasjúkdómar (köld ortopedia)  
Barnaáverkar (heit ortopedia)**

Halldór Jónsson jr

Bæklunarskurðeild LSH og Læknadeild HÍ

# Meðfætt

- Luxatio coxae congenita -  
(Meðfætt liðhlaup í mjöðm)
- ATH: viðbótarfellingar á læri og lægra/(hærra) hné



# Meðfætt

- Einnig kallað: CDH (Congenital Dislocation of Hip)
  - Ortholani próf
  - Rtg: Shentons lína

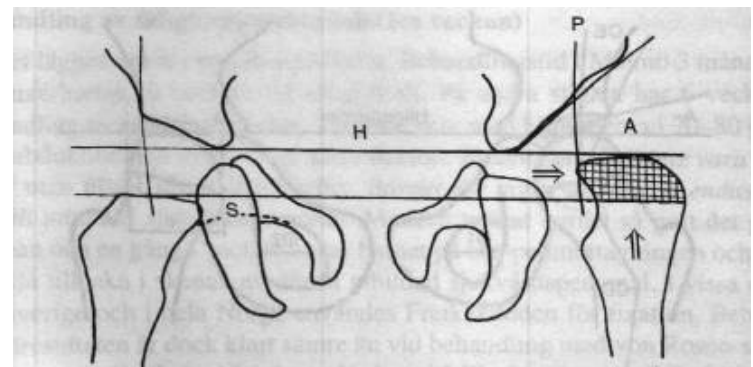
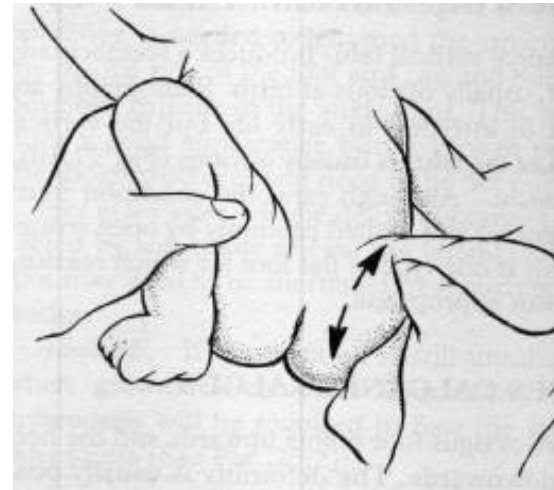
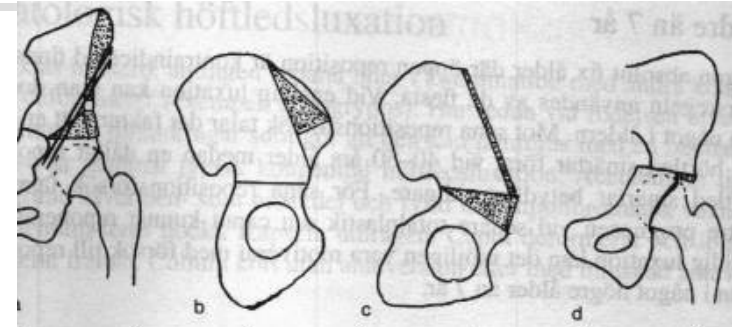
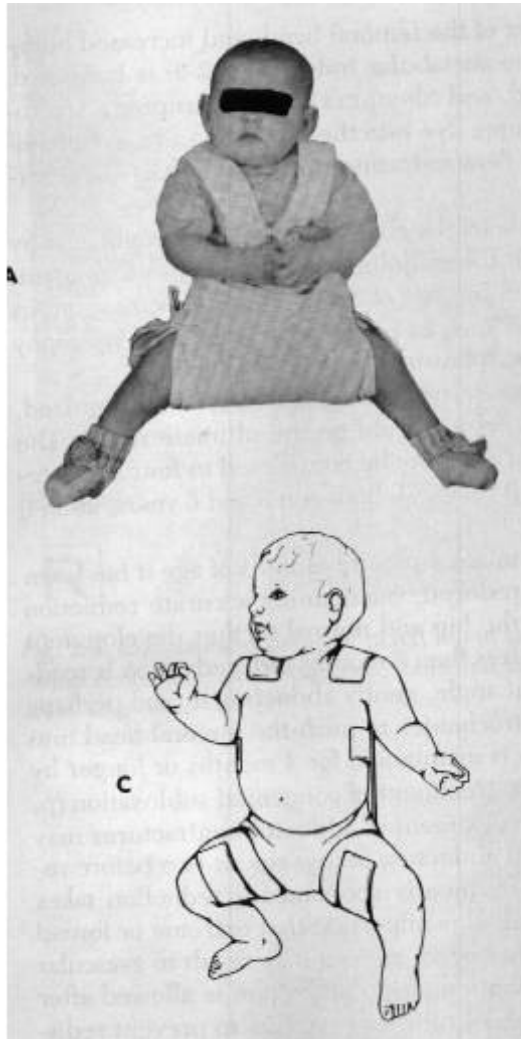


Fig. 6.2 Röntgenologisk diagnostik av kongenital höftledsluxation redan i födsel och innan caputkärnan förkalkats med användande av Shentons linje. Observera att röntgenologen måste vara förtrogen med luxationsmanövrarna. Håll höftleden i luxerat läge vid röntgenundersökningen. H = Hilgenreit, P = Perkins linje, A = Acetabularvinkel, S = Shentons linje.

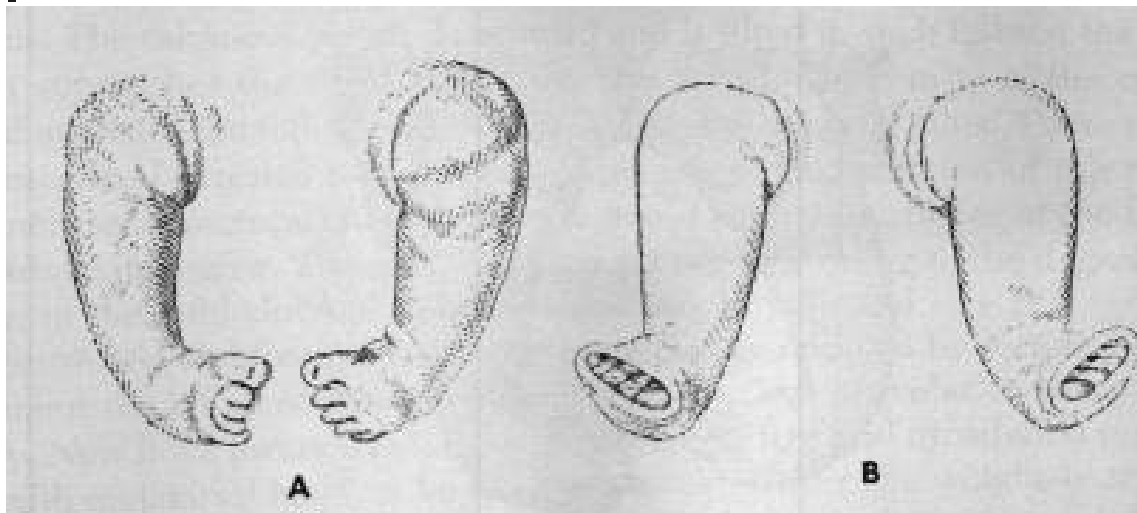
# Meðfætt

- Frejka buxur
- - næstu 6-8 v
- Von Rosen skinna
- - fyrstu 6-8v

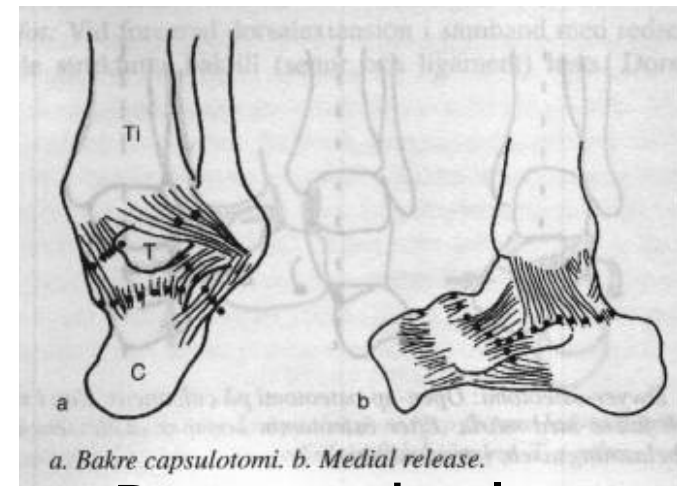


- Salter osteotomia
- Chiari osteotomia

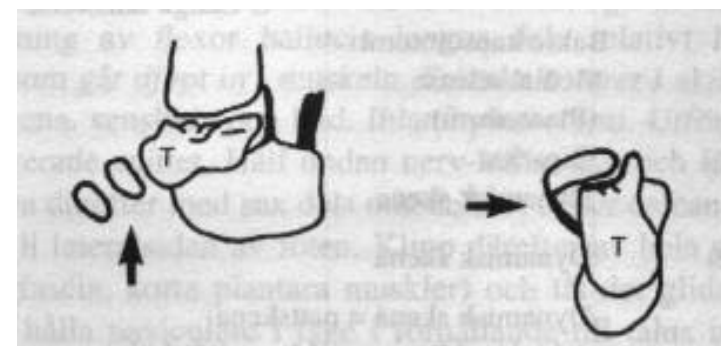
# Meðfætt



- Pes equinovarus adductus (klumbufætur)
  - Fyrir og eftir "redressing"

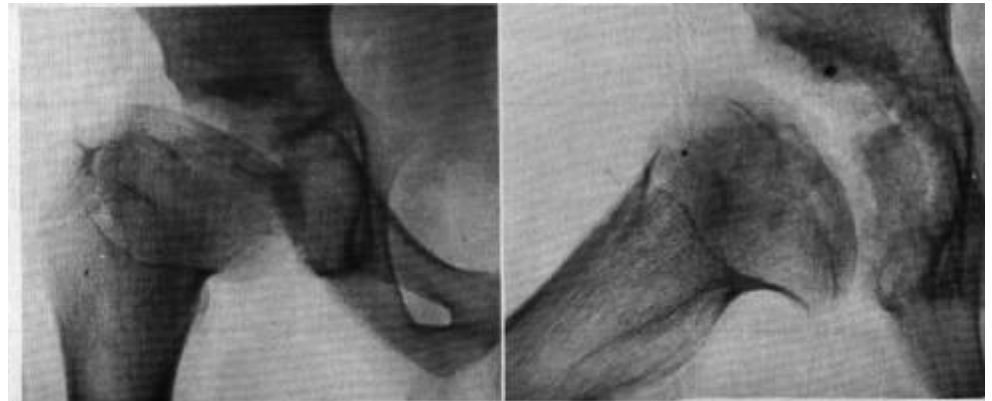
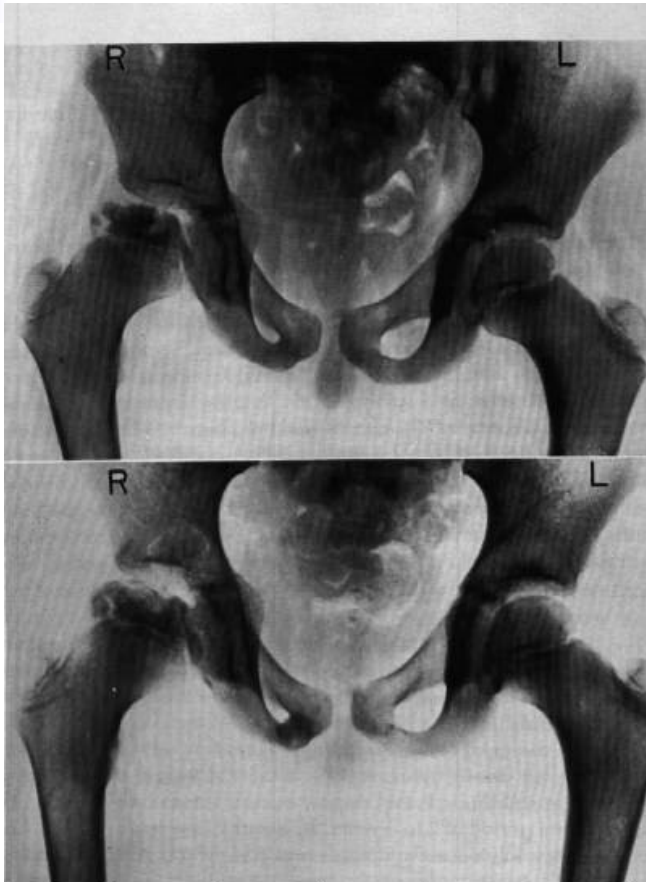


Post-med release



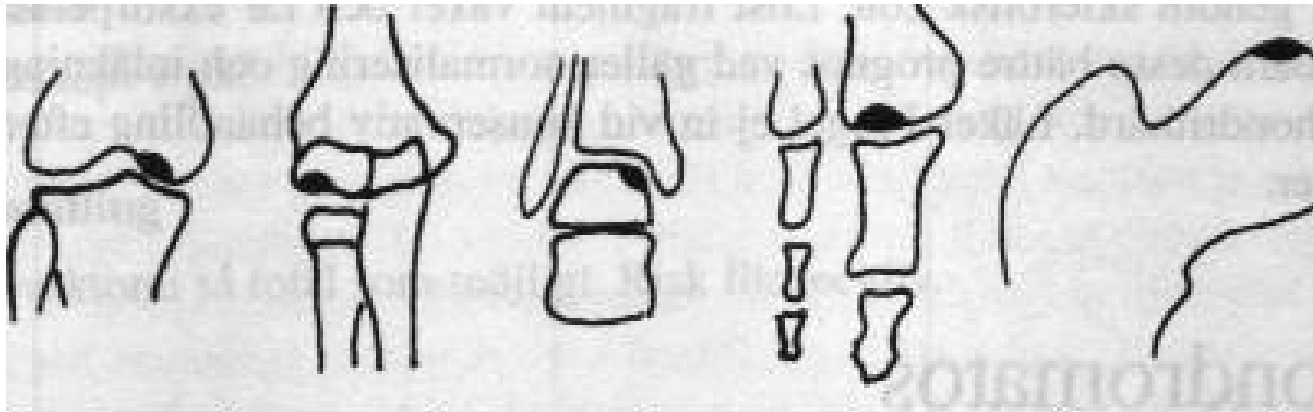
Talus necrosis

# Blóðrásartruflun



- Coxa magna
- Perthes –
  - “caput necrosis” í mjöðm

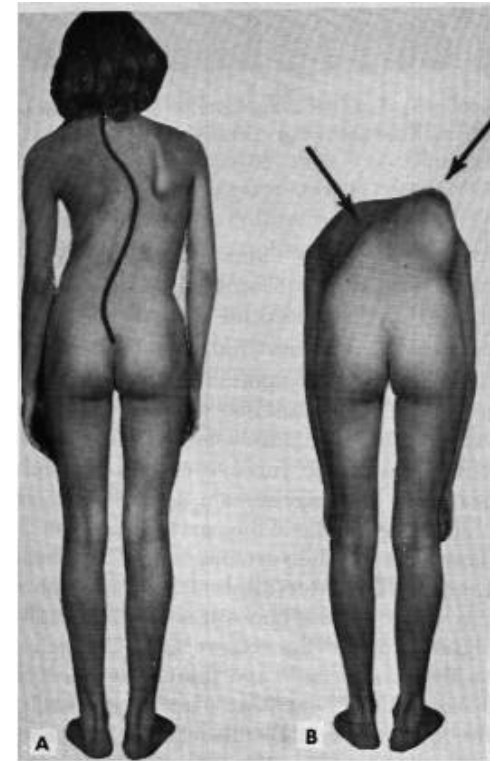
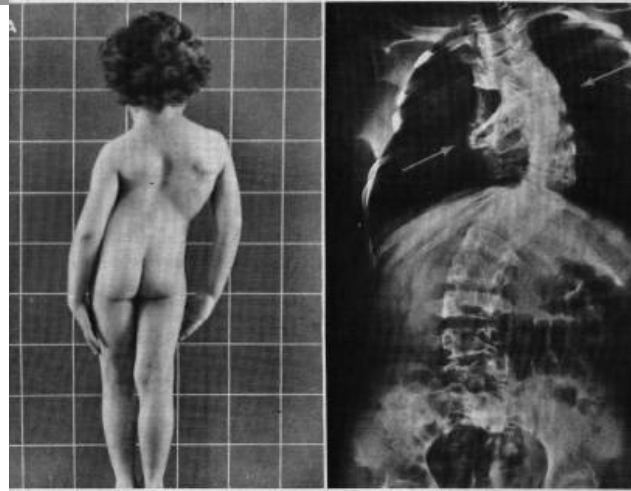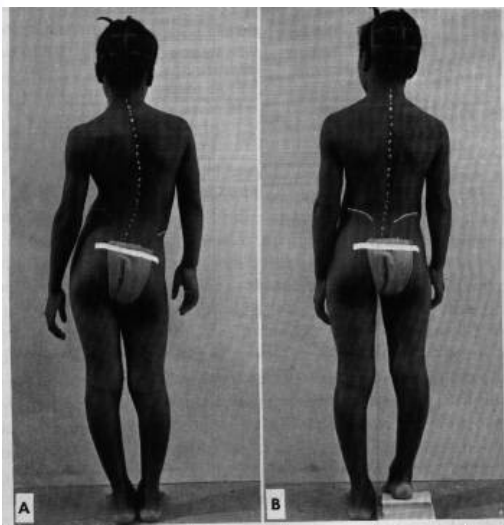
# Blóðrásartruflun



- "Osteochondritis"
  - getur orðið "dissecans" (laus biti)




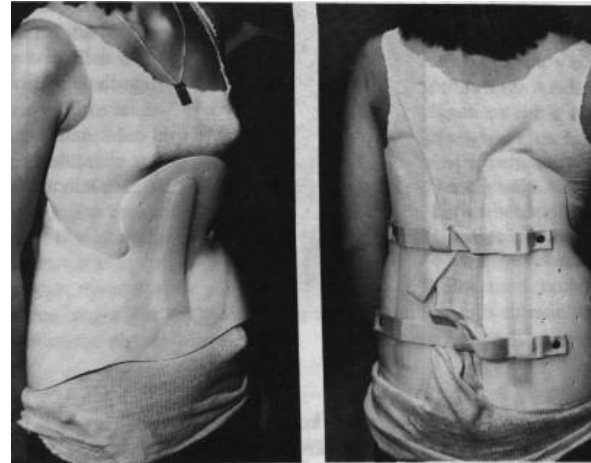
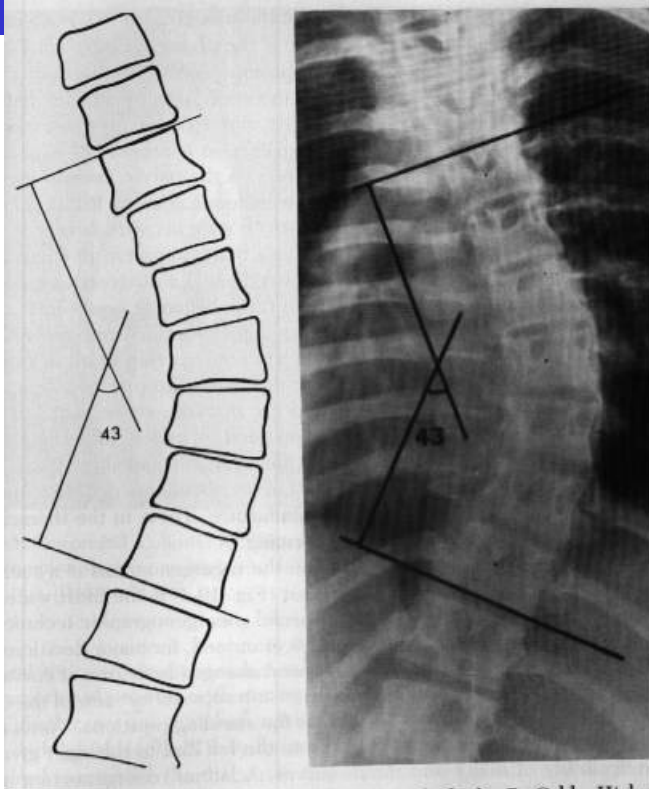
# Vaxtaraflogun - truflun



- Scoliosis – hryggskekkja
  - Functional
  - Congenital
  - Idiopathic

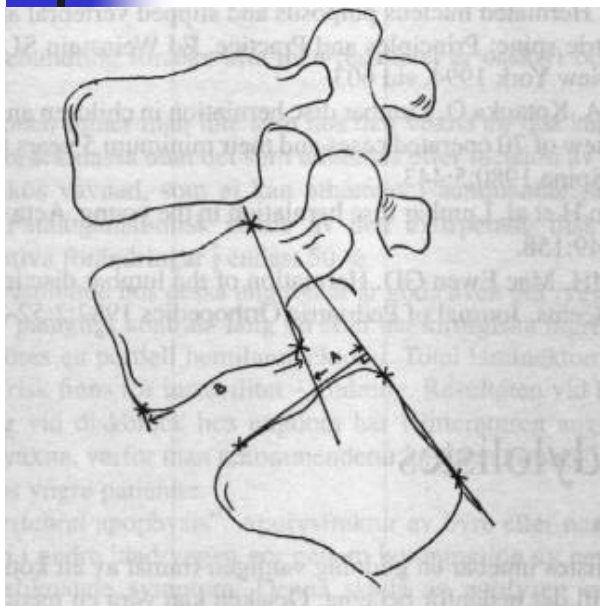


# Vaxtar aflögun - truflun

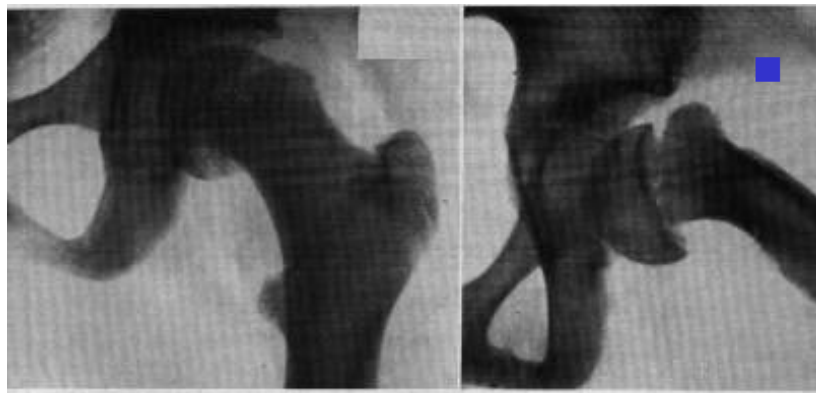


- Scoliosis – hryggskekkja
  - Cobbs horn
  - Boston belti
  - Aftari upprétting og spening

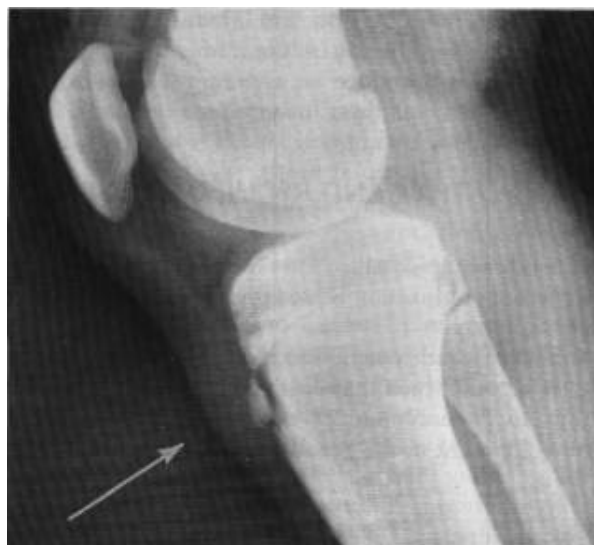# Vaxtarafloegun - álag



- Spondylolysis
  - hryggskrið

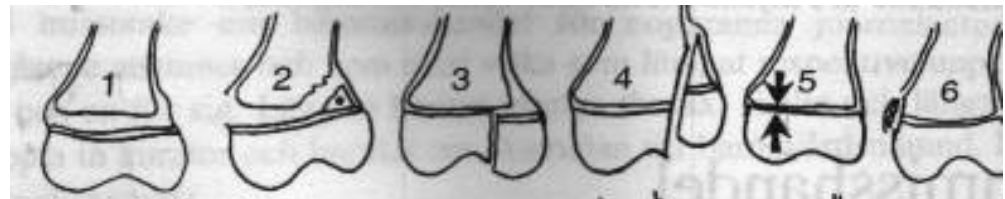


- Epifysiolysis
  - vaxtarlínuskrið

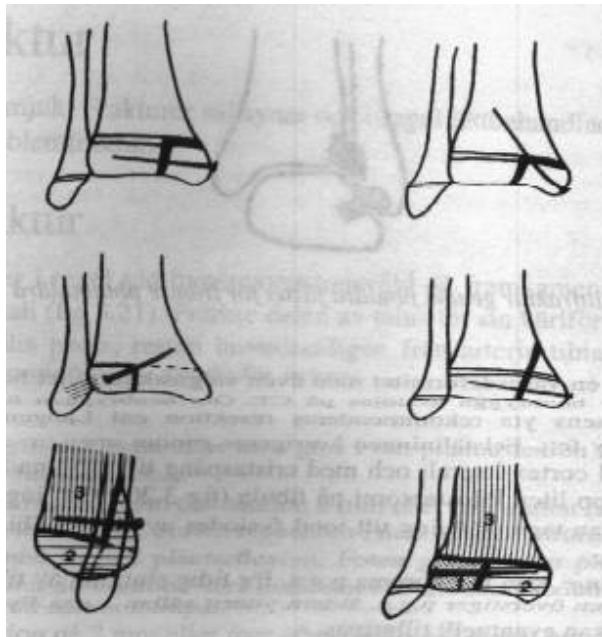


- Osgood-Schlatter
  - Slatter sjúkdómur

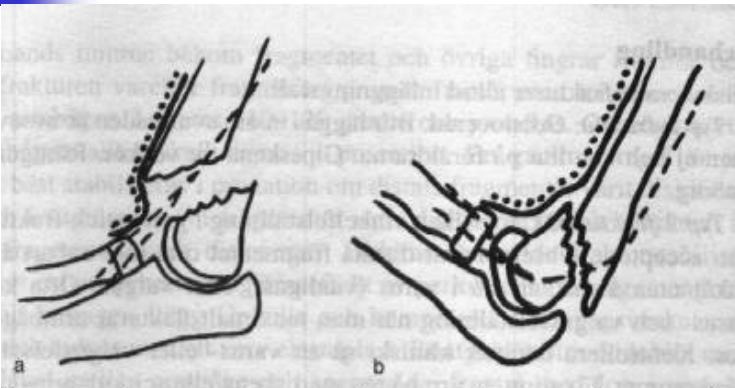
# Áverkar - brot



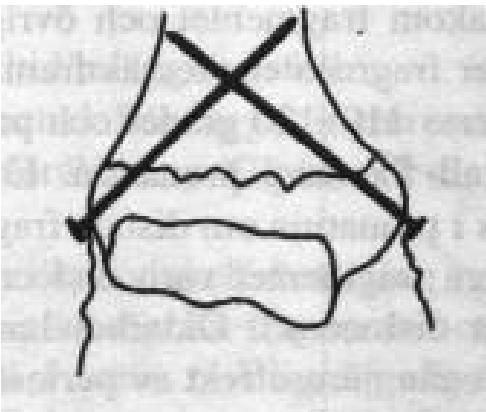
- Vaxatarlínuáverkar: Salter-Harris



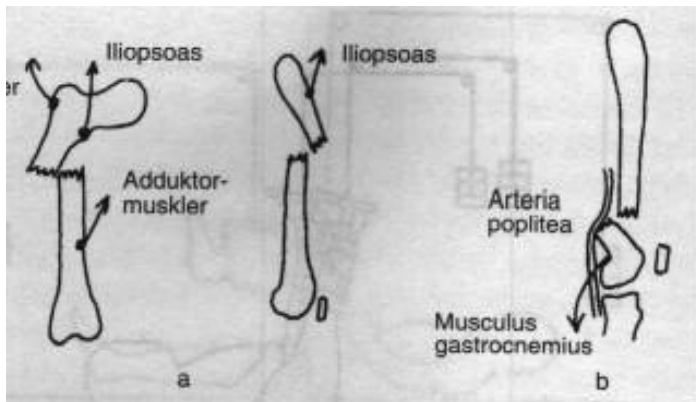
# Áverkar - brot



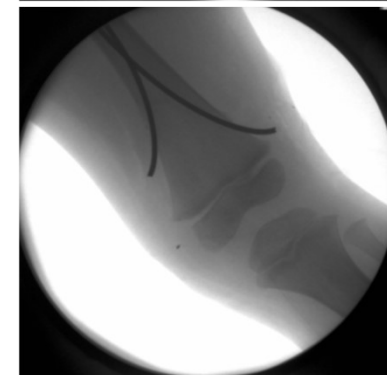
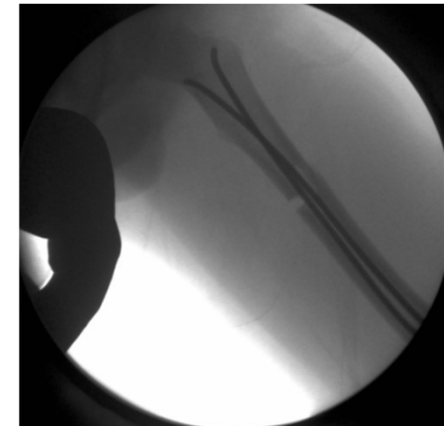
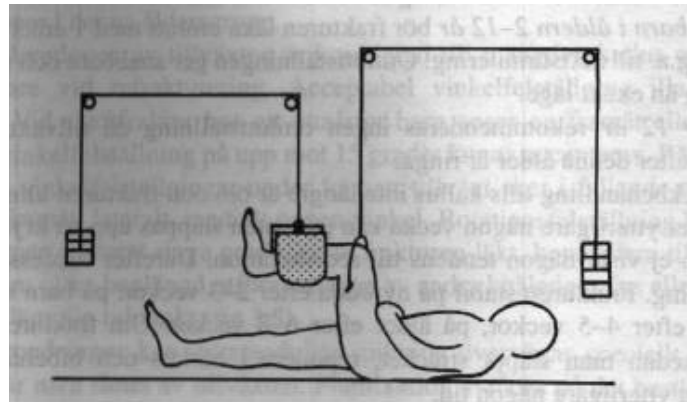
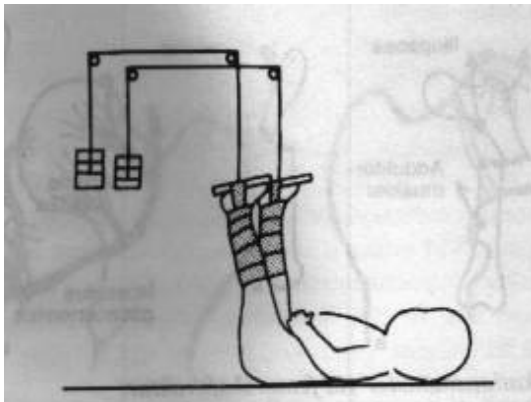
- Supracondylar humerus brot
  - ATH púls - compartment
  - Lokað/ opið rétt og pinnað



# Áverkar - brot

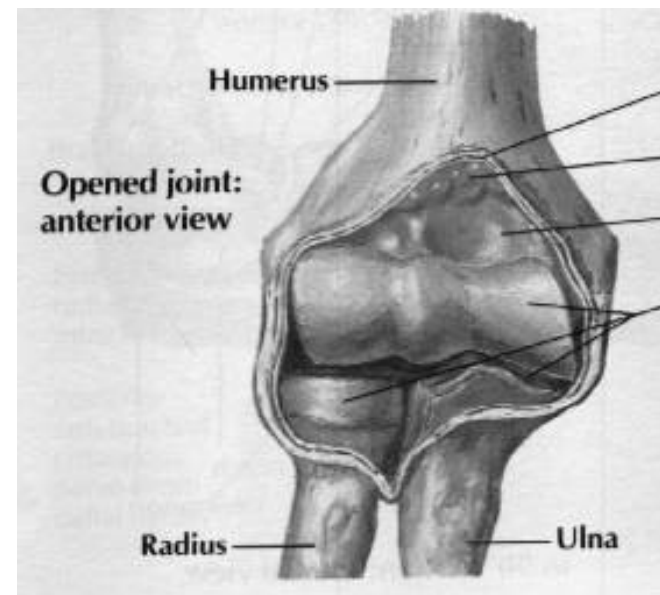
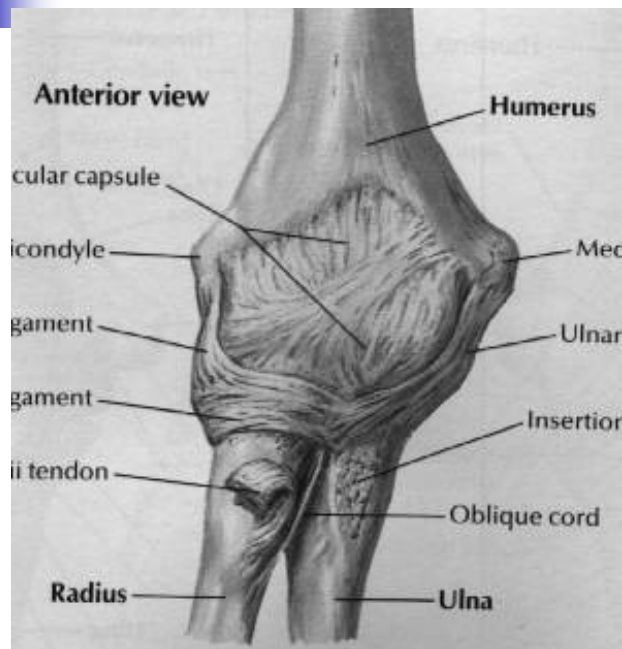


- Skaftbrot
  - Strekkur (Gallow og 90-90)
  - Mergnagli (TEN)





# Áverkar - liðhlaup



- Olnbogi
  - “Pig / nursemaids” liðhlaup