


# STOÐKERFISVANDAMÁL1:

## slitgigt, öldrun



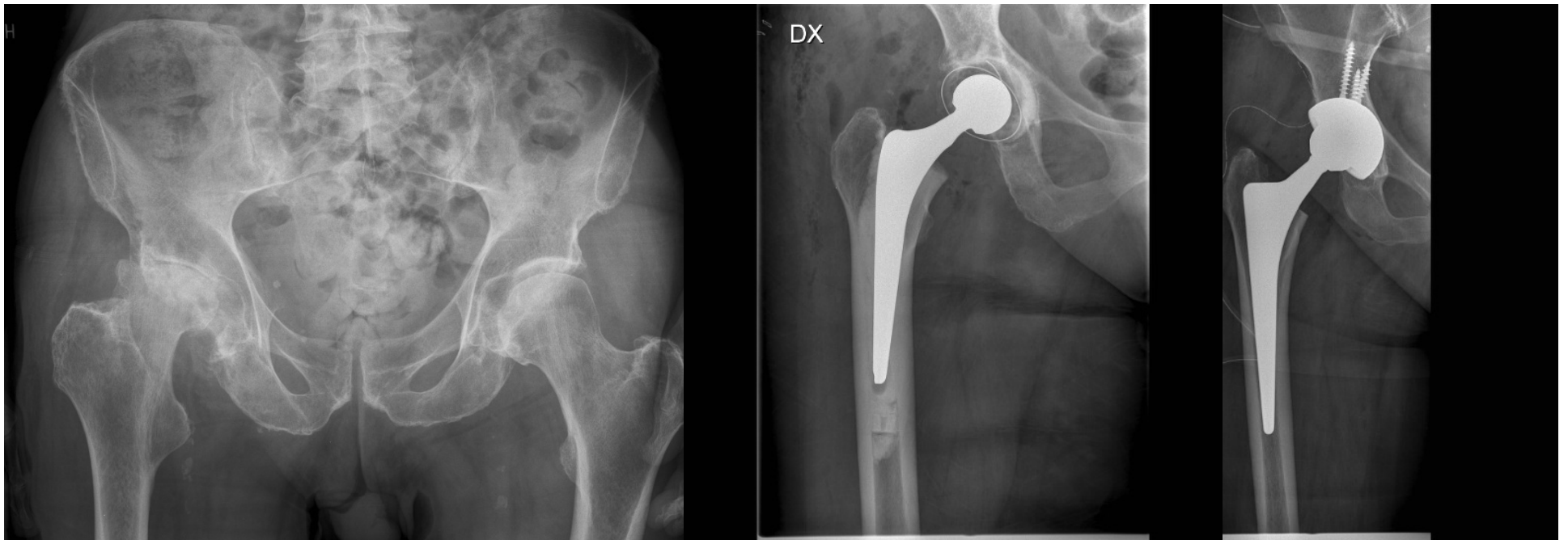
Halldór Jónsson jr

# Helstu bæklunarvandamálin!

- Slitgigt í stórum liðum
- Öldrun
- Sýking í liðum og beinum
- Æxli og meinvörp



# Slitgigt í stórum liðum: mjöðm

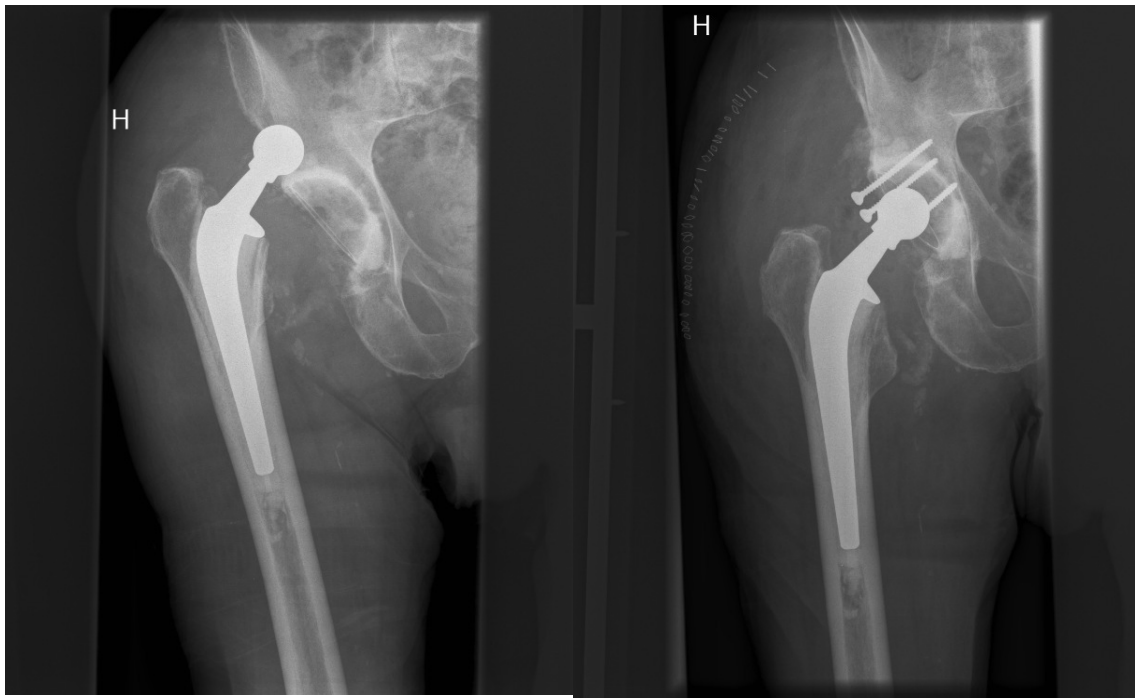


Frumslit (primary) eða  
v/annarra orsaka (secondary)

Cement

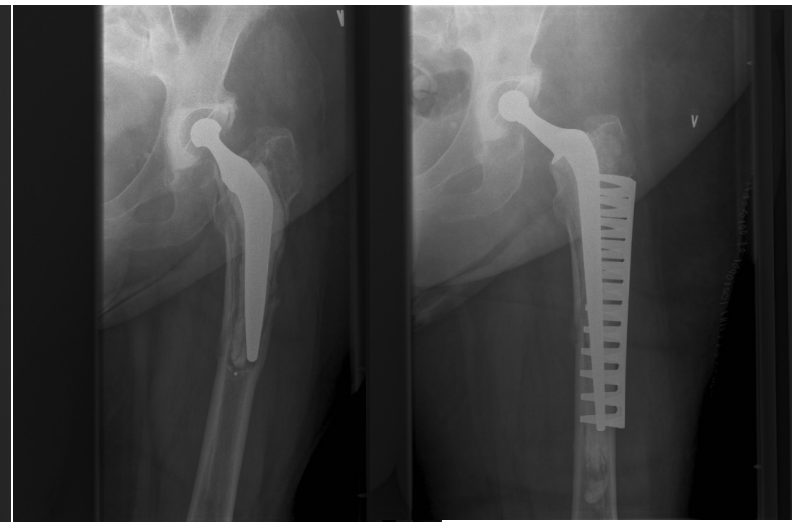Ekki cement

# Slitgigt í stórum liðum: mjöðm



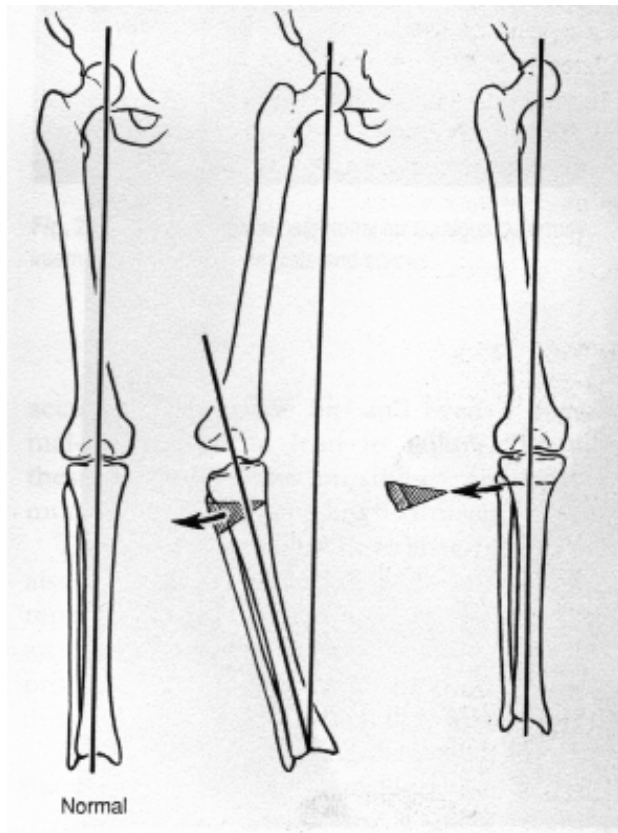
Liðhlaup

Skálarauki

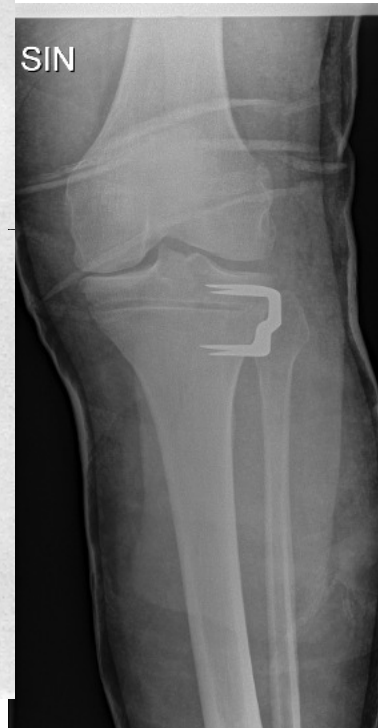

Periprosthetic  
brot

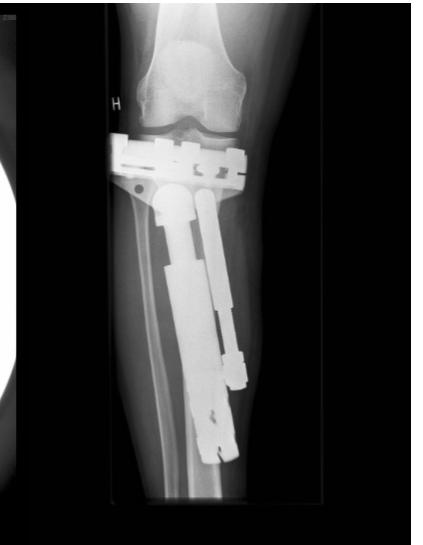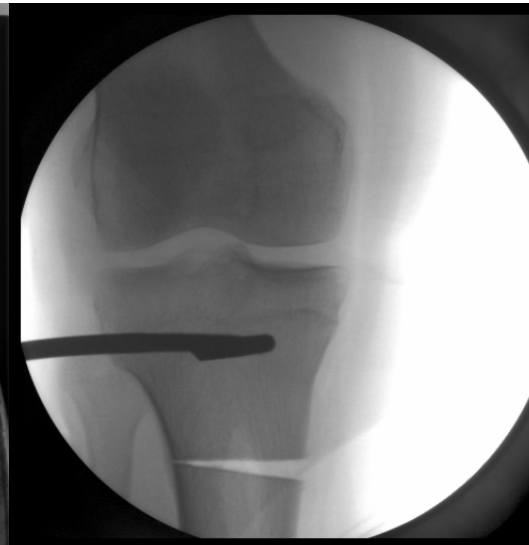# Slitgigt í stórum liðum: hné



HKA vinkill

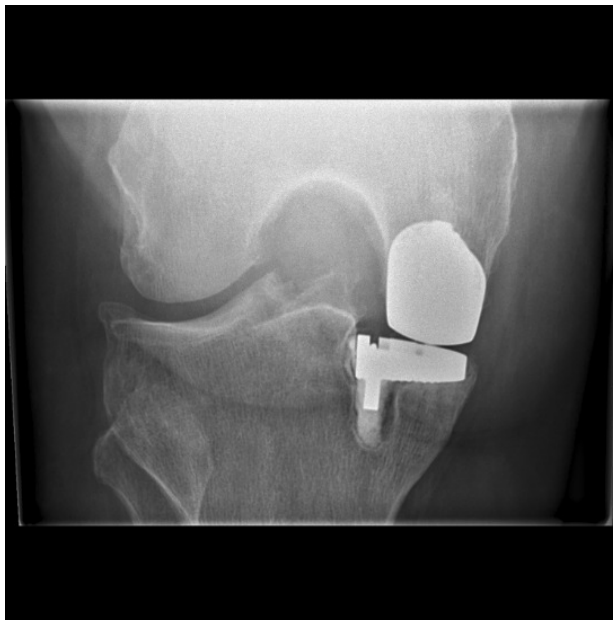


Mínus osteot

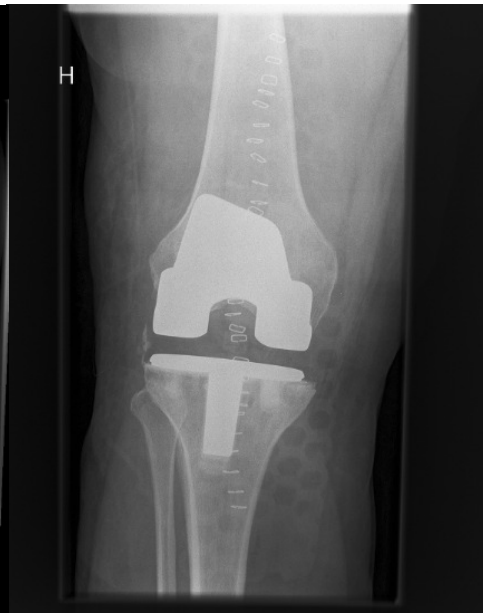

Plús osteotomía:  
Ex fix eða bein + plata

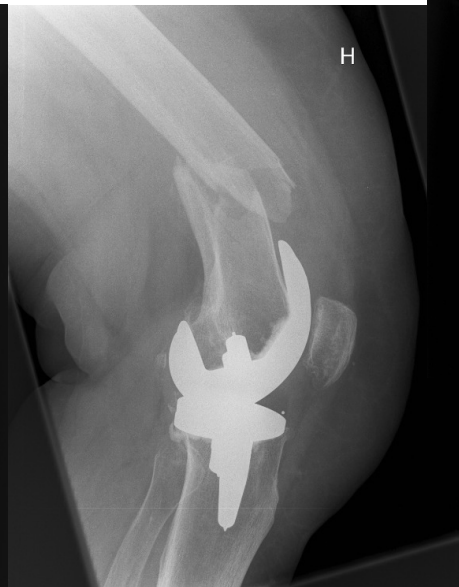# Slitgigt í stórum liðum: hné



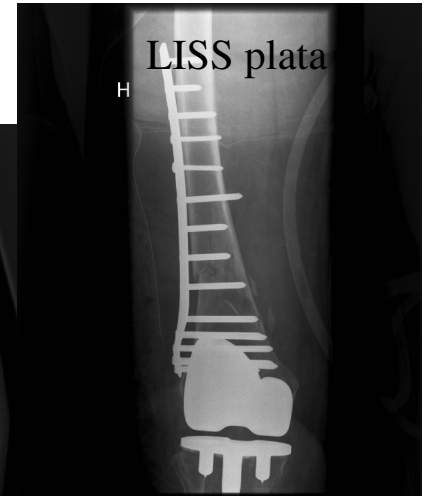
Hálfliður



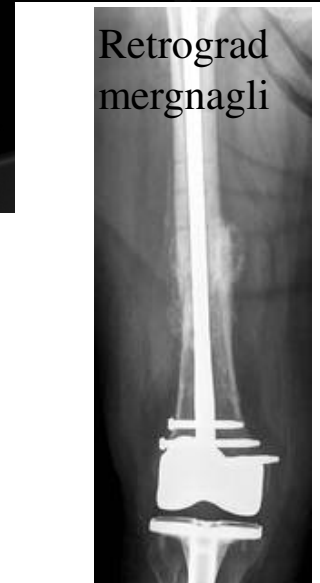Heilliður



Brot ofan hnéprótesu

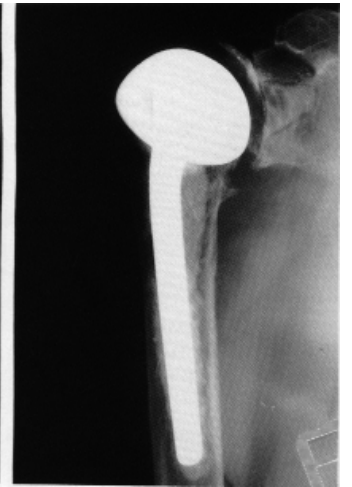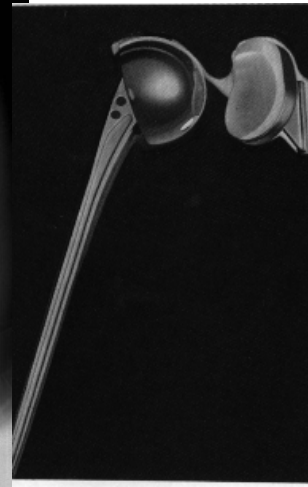

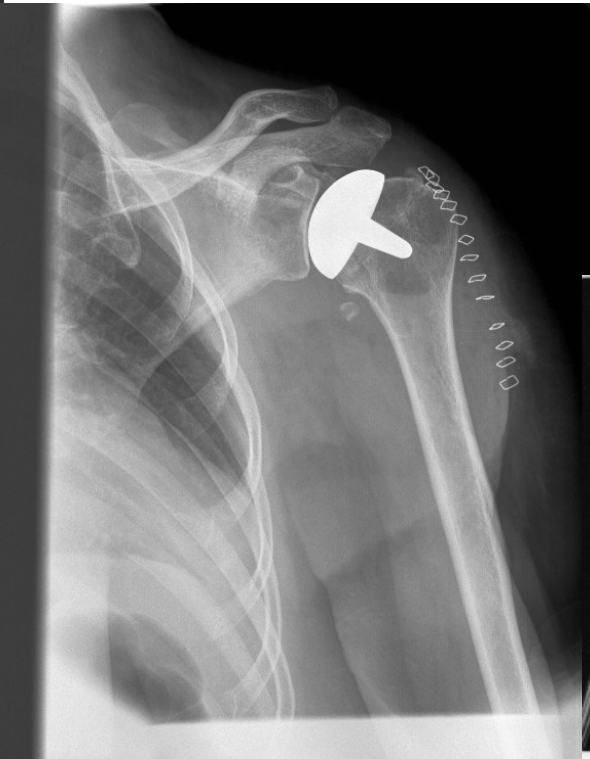
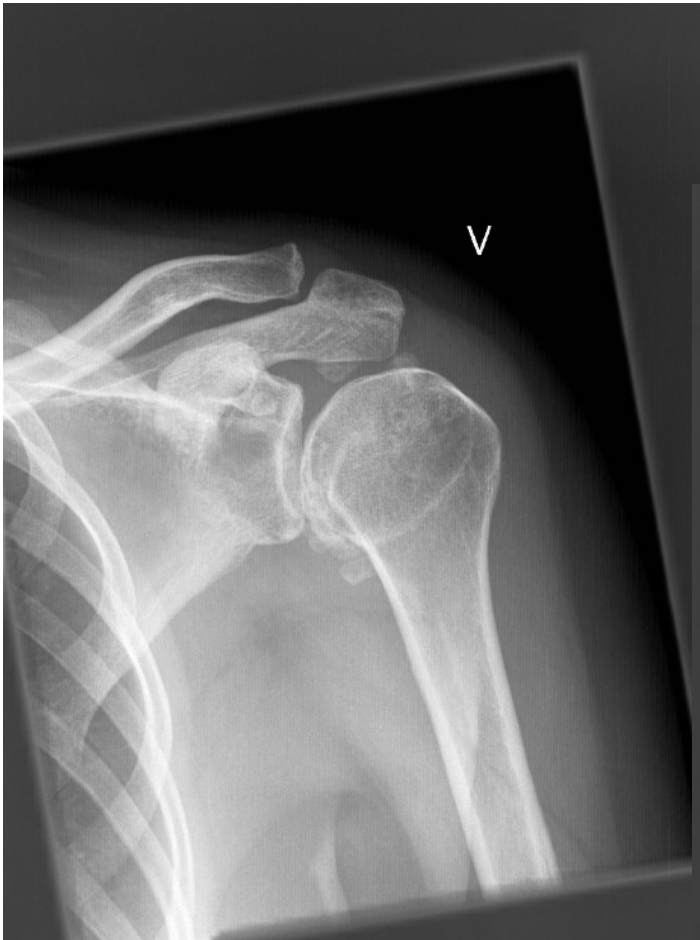LISS plata



Retrograd  
mergnagli

# Slitgigt í stórum liðum: öxl



Resurfacing

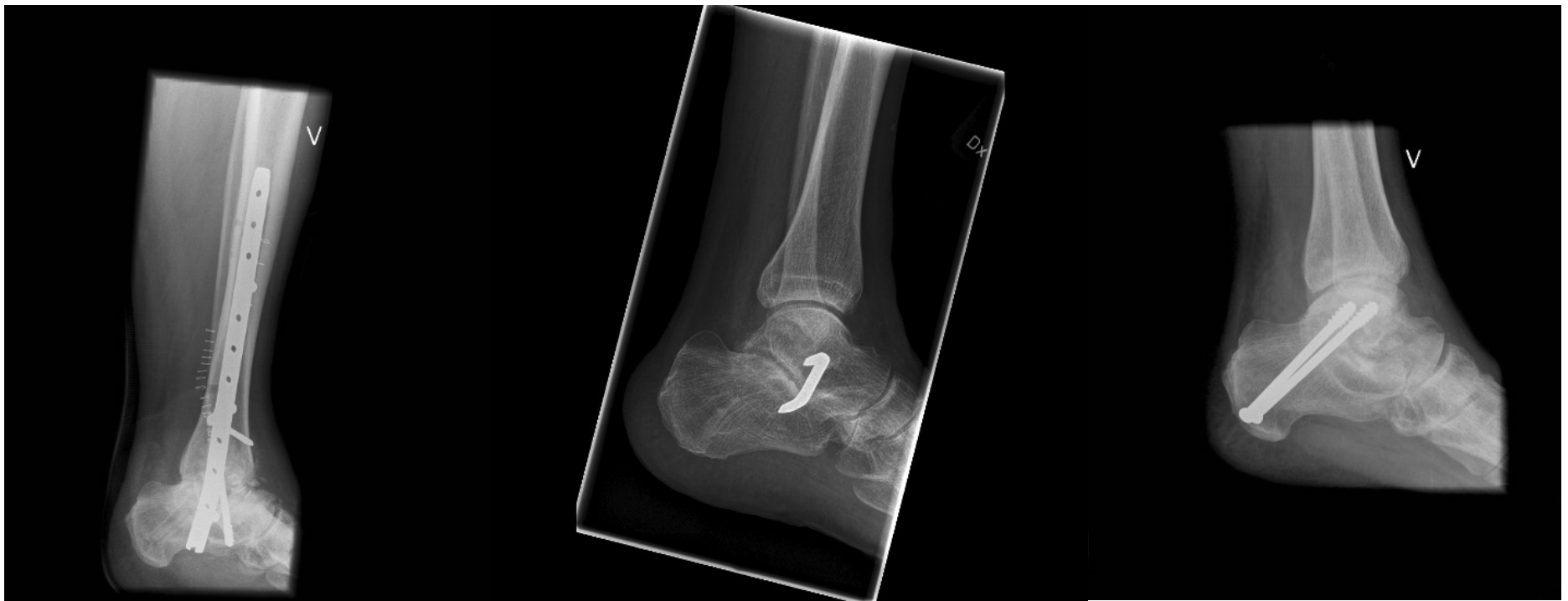Mono-

Bi-polar

# Slitgigt í stórum liðum: ökkli

-talocrural

-subtalar



Naglar

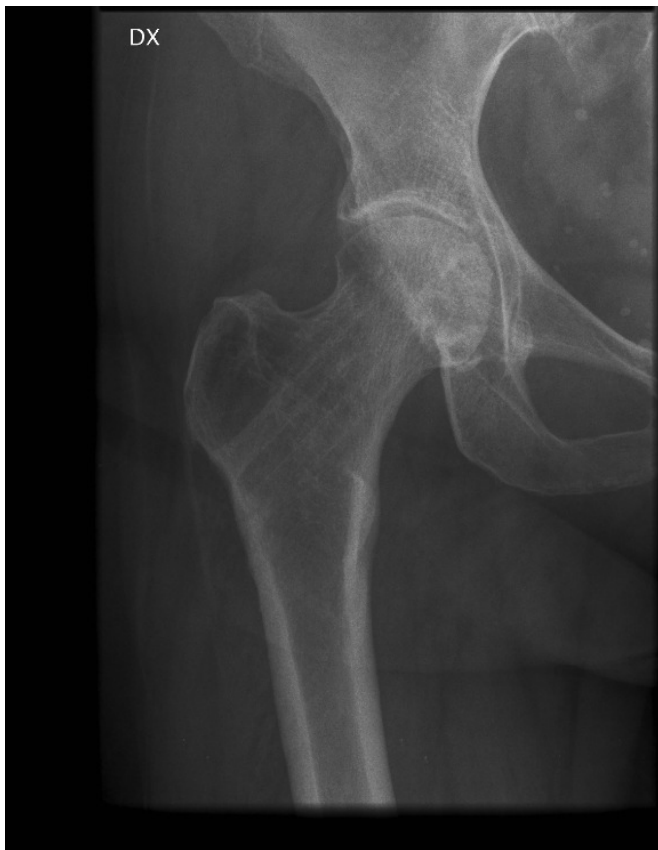Zinklar

Skrúfur

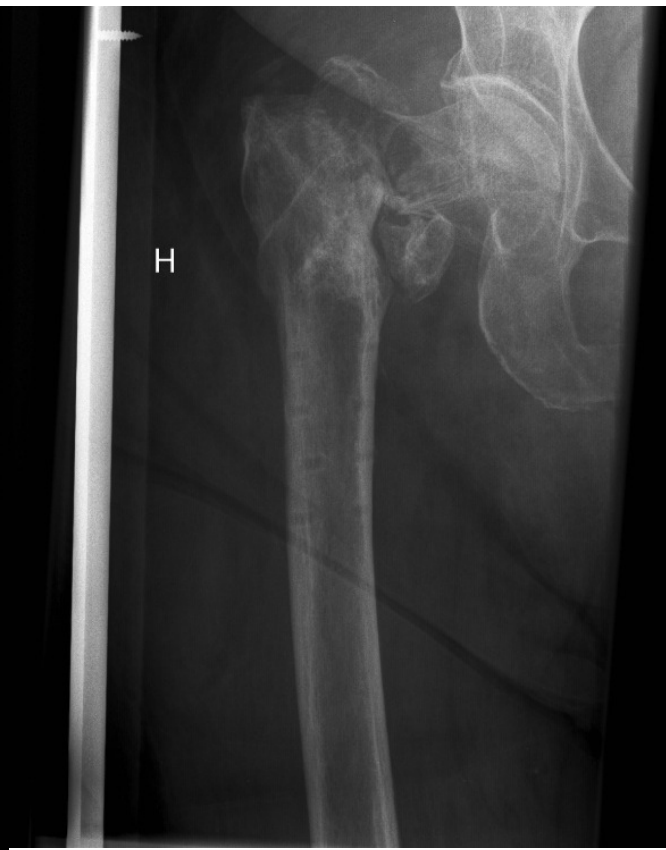

# ..... öldrun

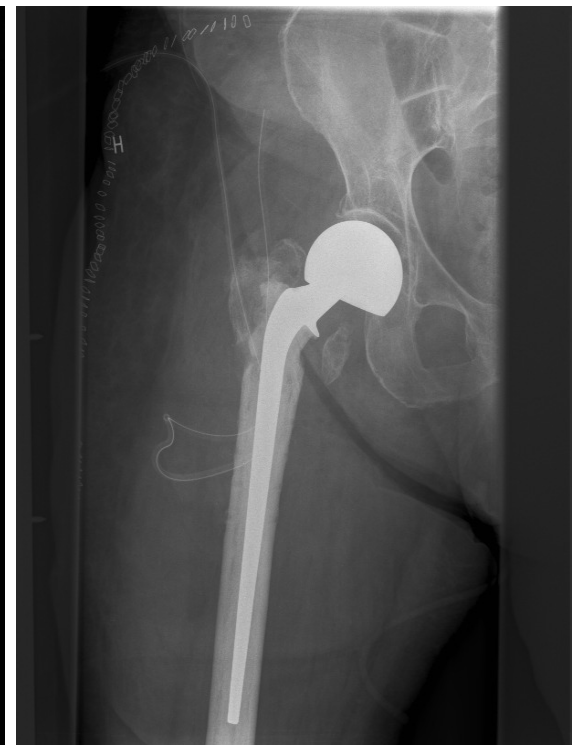## Afleiðingar mjaðmabrota



Caput necrósa e. Collum fx



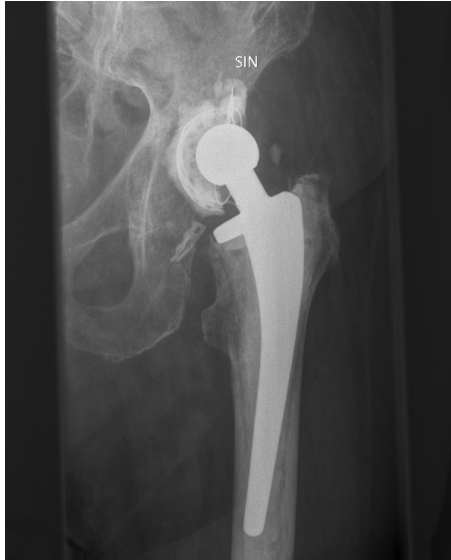Pseudarthrosa e. Trokanter fx



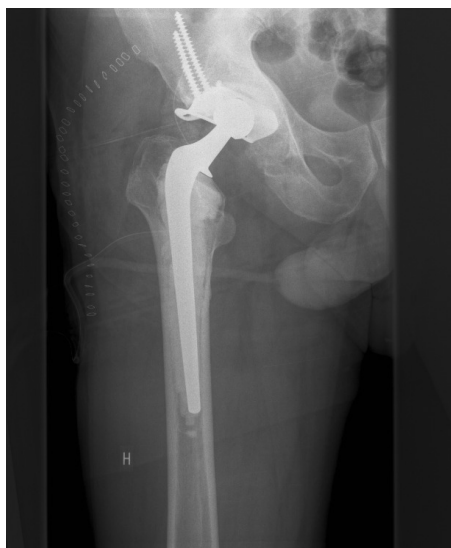Bi-polar gerviliður

# ..... öldrun

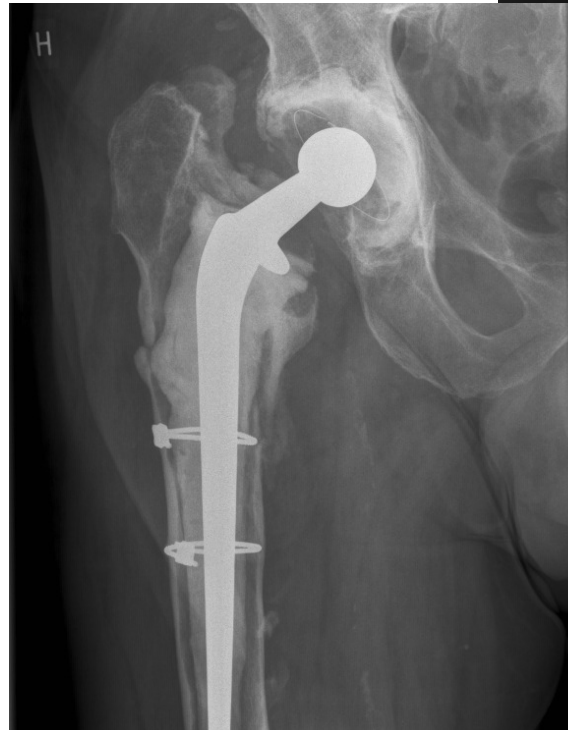## Lausir gerviliðir (mjaðmir og hné)



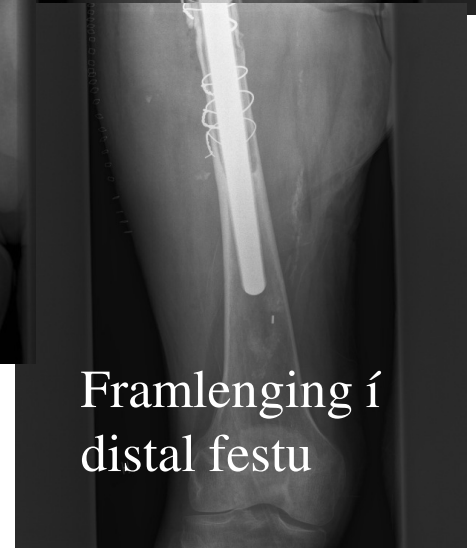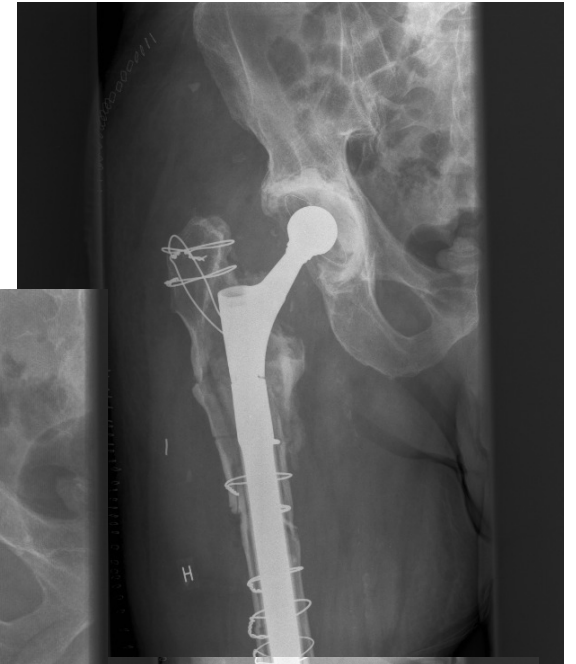Laus bolli



Acetabular styrking

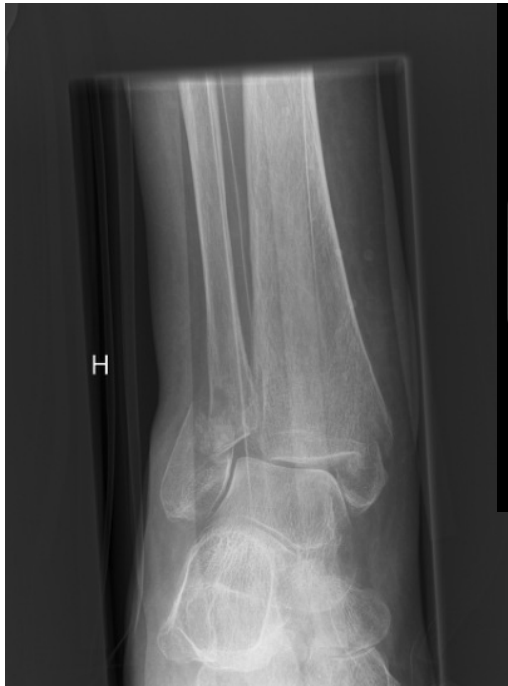

Laus stilkur

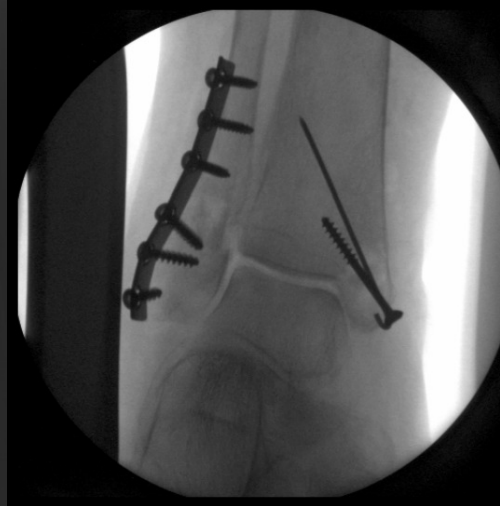

Framlenging í distal festu

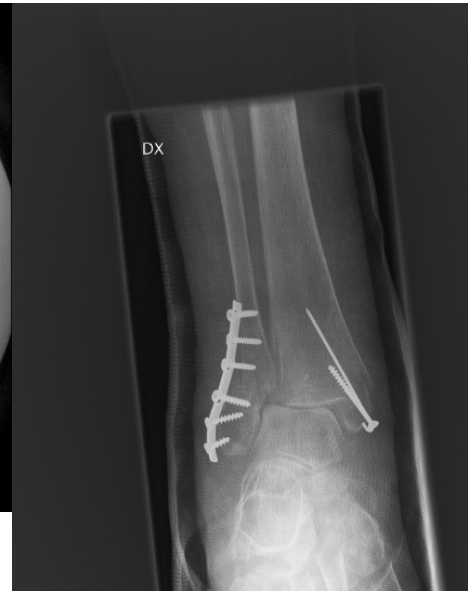# ..... öldrun



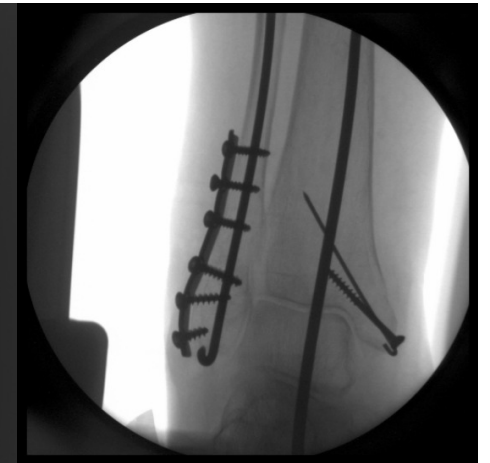“Osteoporotic”  
ökklabrot



“Hefðbundin ORIF”

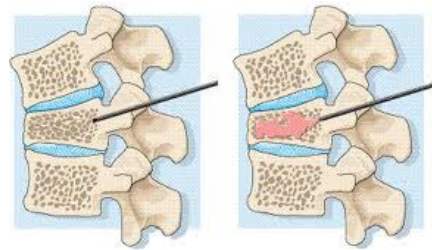
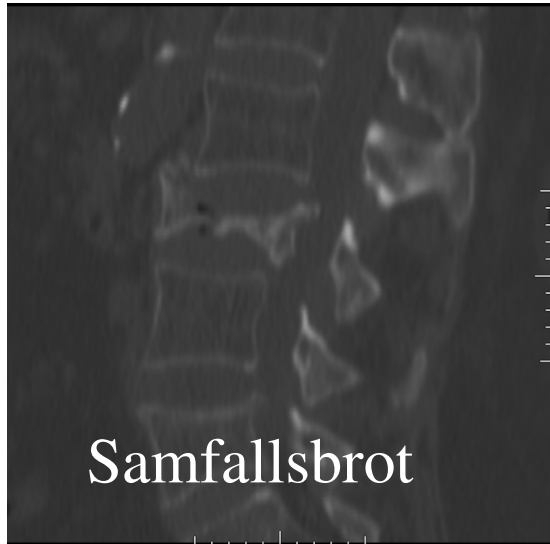

Festibúnaður  
heldur ekki .....

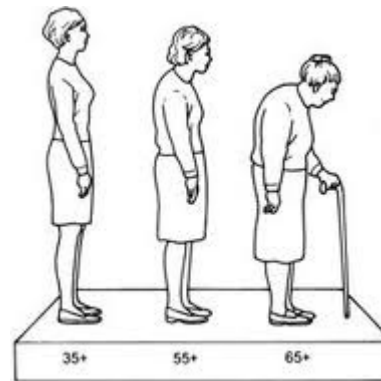
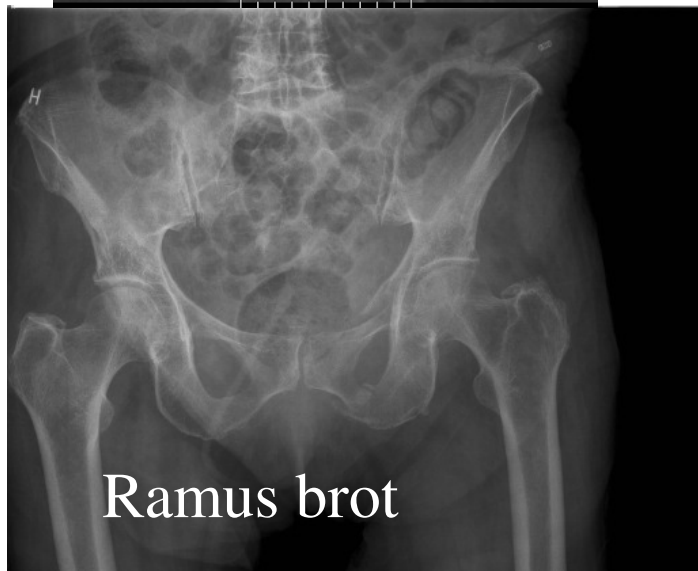

“First line of defence”

# ..... öldrun



Vertebroplasty





*TAKK!*

---