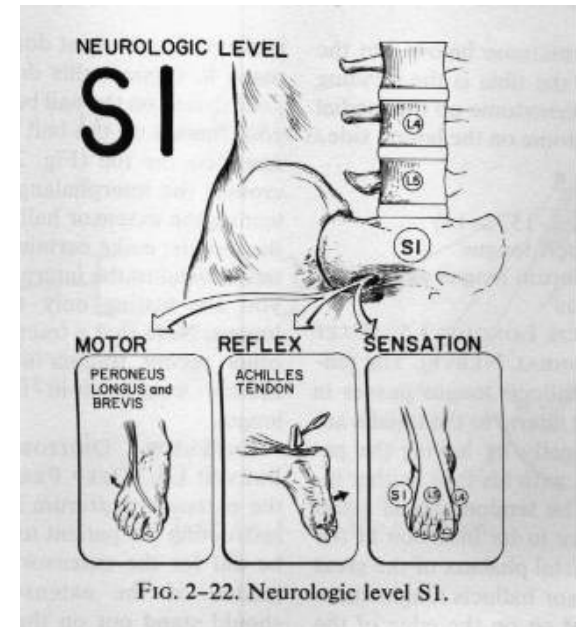
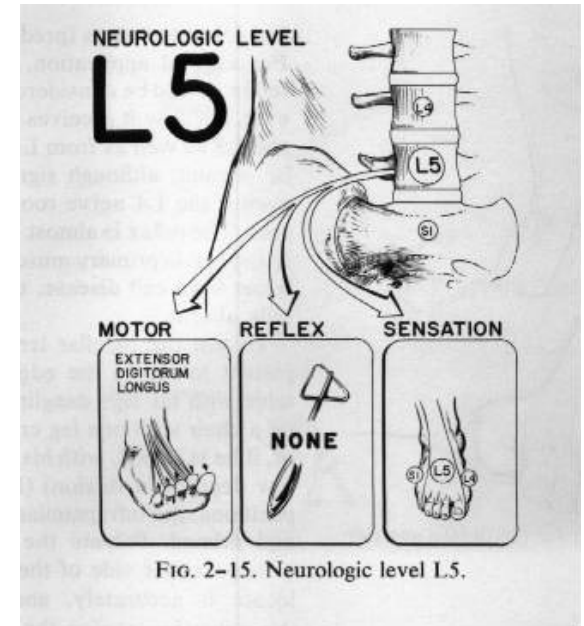
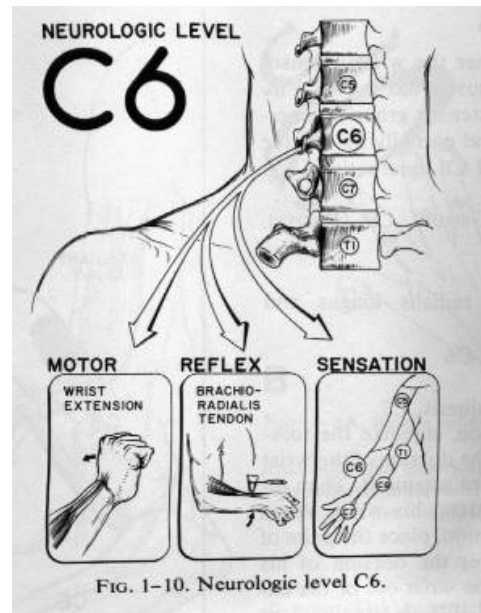
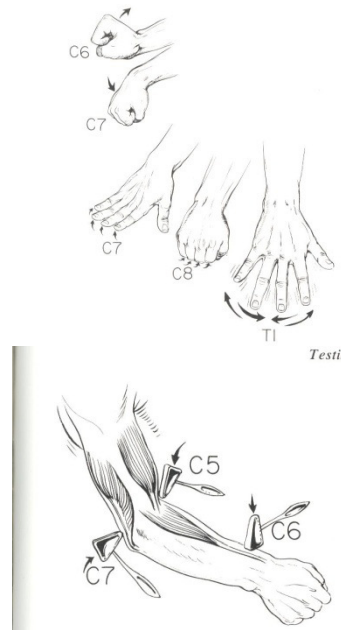
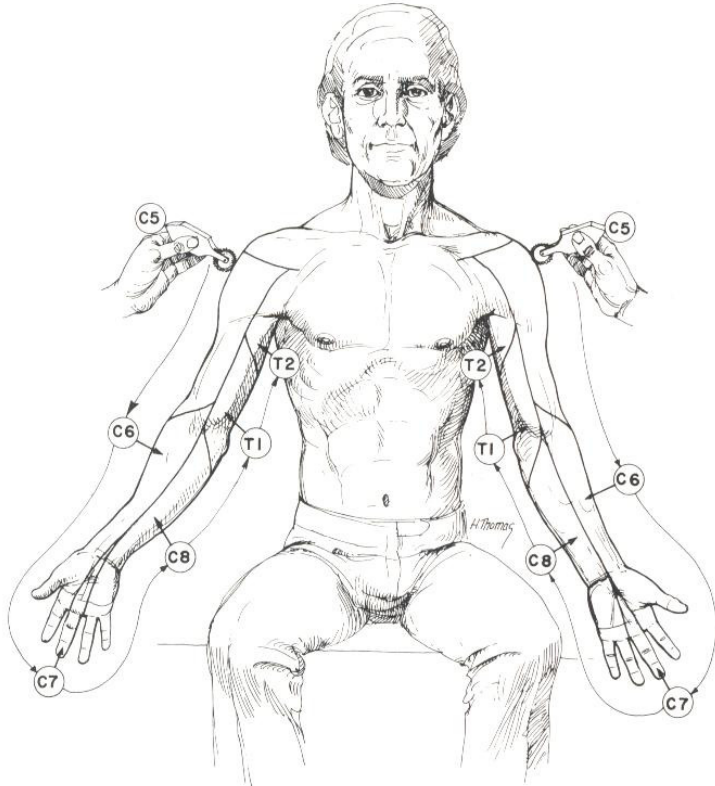




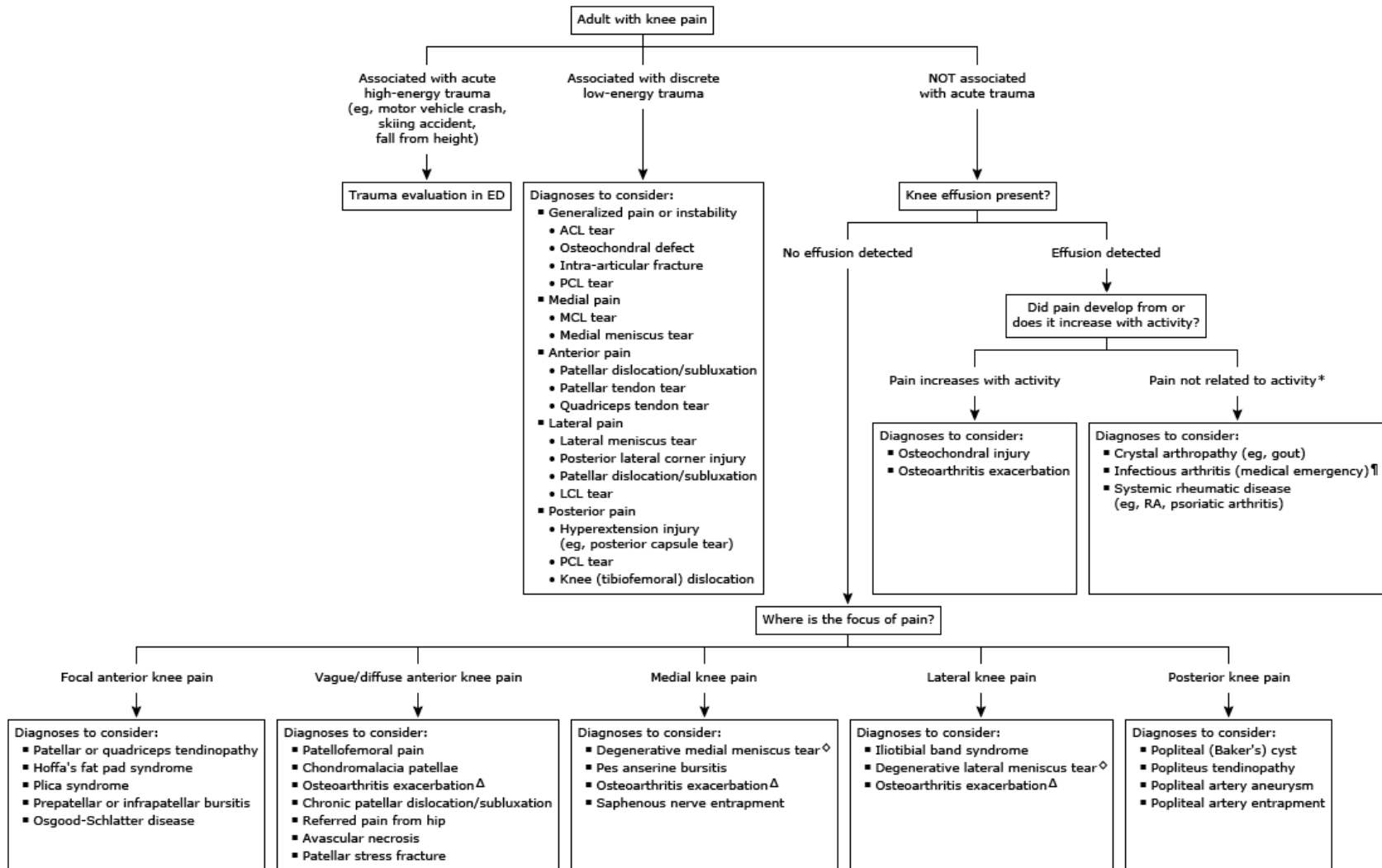
Anatomia stoðkerfisins: Eru til Ortopediskar taugar?



“Lausn eða vandamál”!



“Verkur í hné”!



“Samband”: hné, mjöðm, bak ?

